

The Endocrine System

Xue Hui

Department of Histology & Embryology

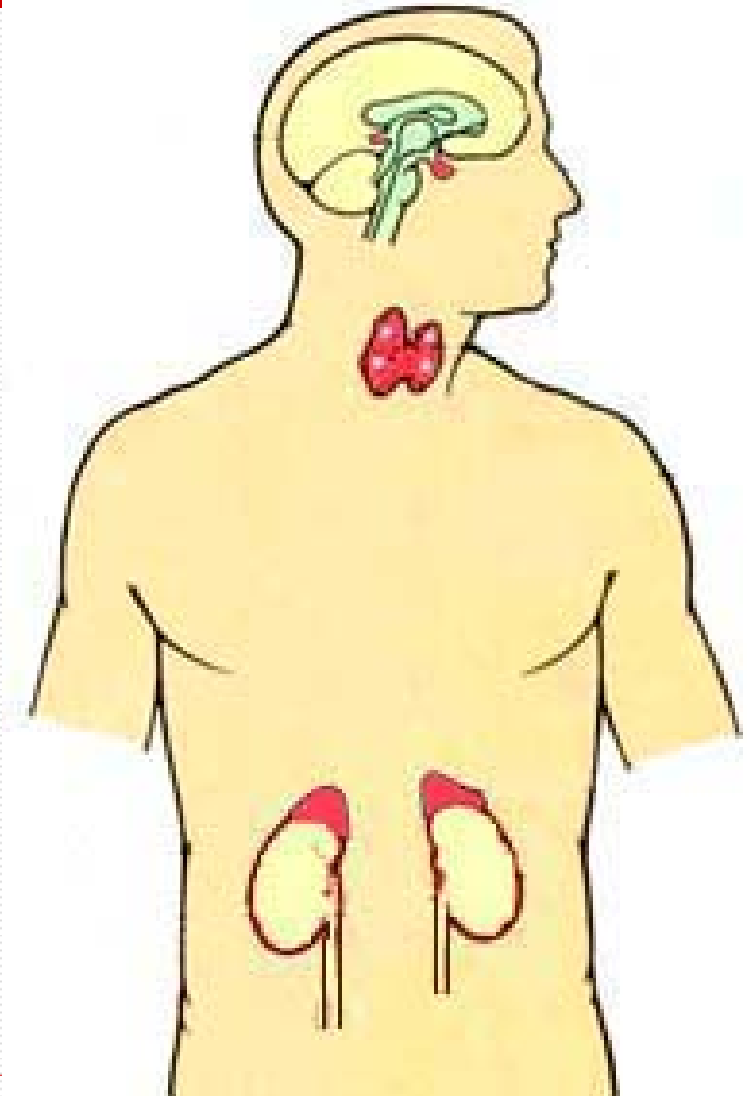
Structural components of the endocrine system

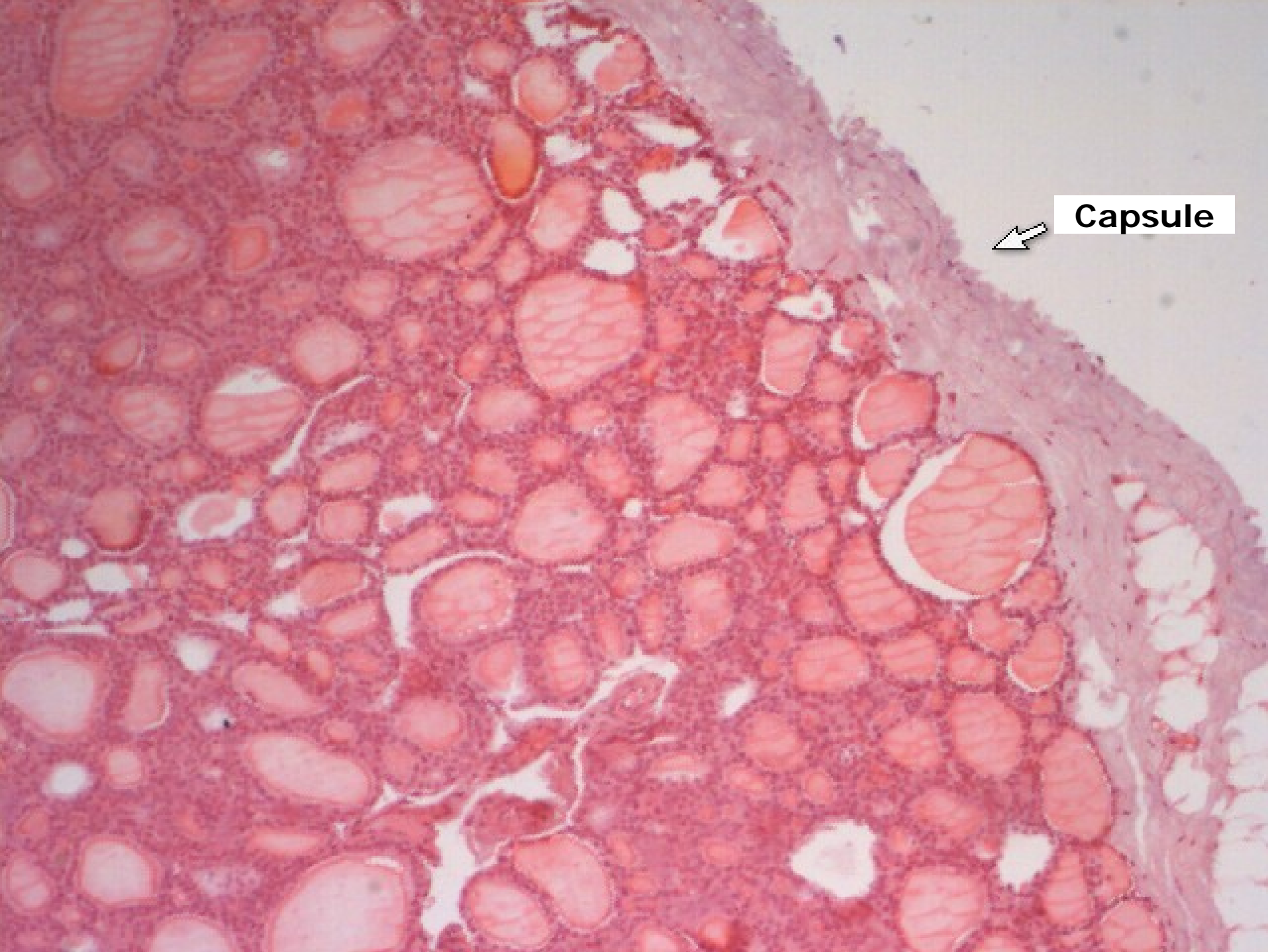□ Endocrine glands

- Thyroid gland
- Parathyroid gland
- Adrenal gland
- Hypophysis
- Pineal body

□ Endocrine cells

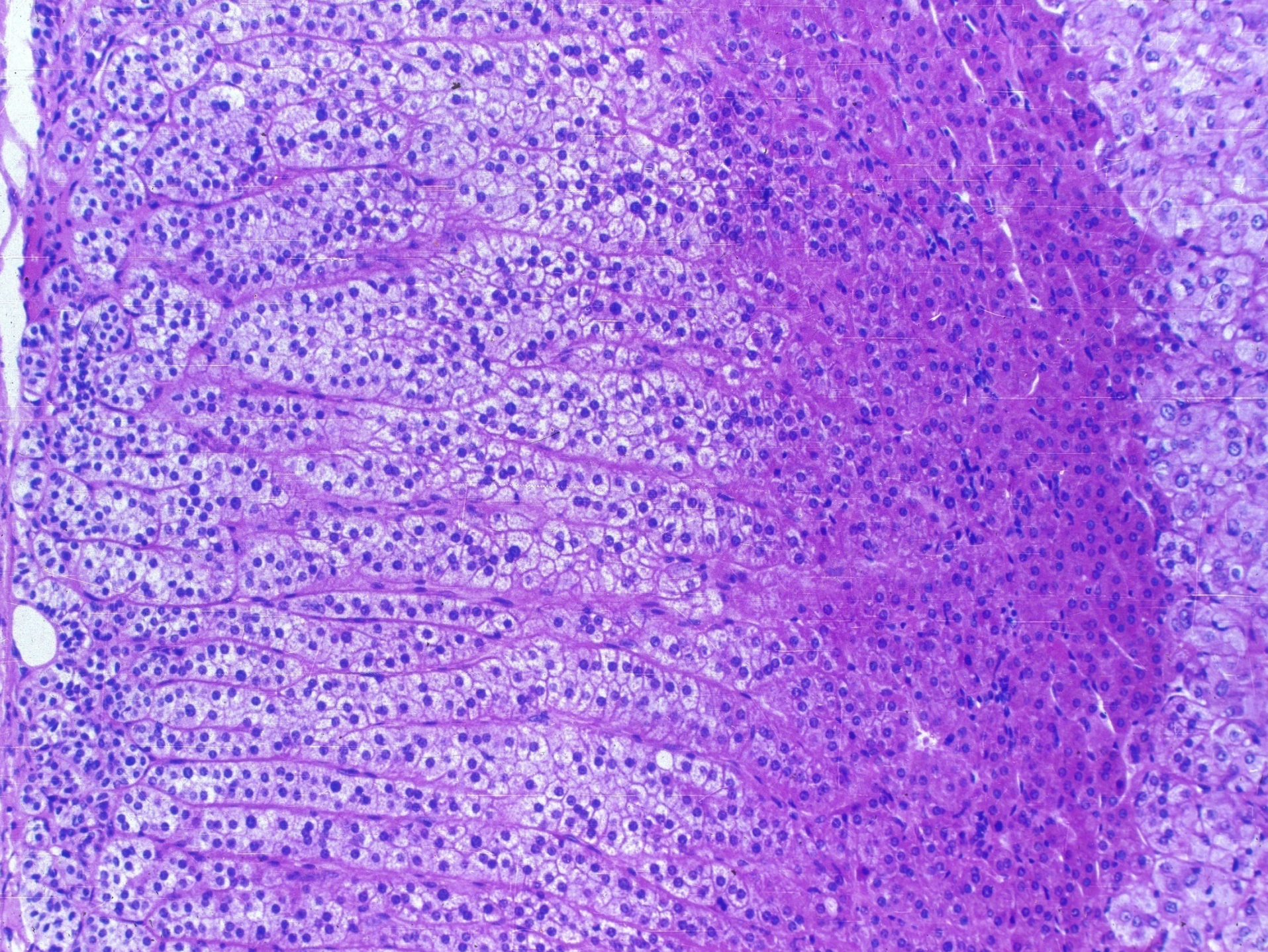
- Protein-secreting cells
- Steroid-secreting cells



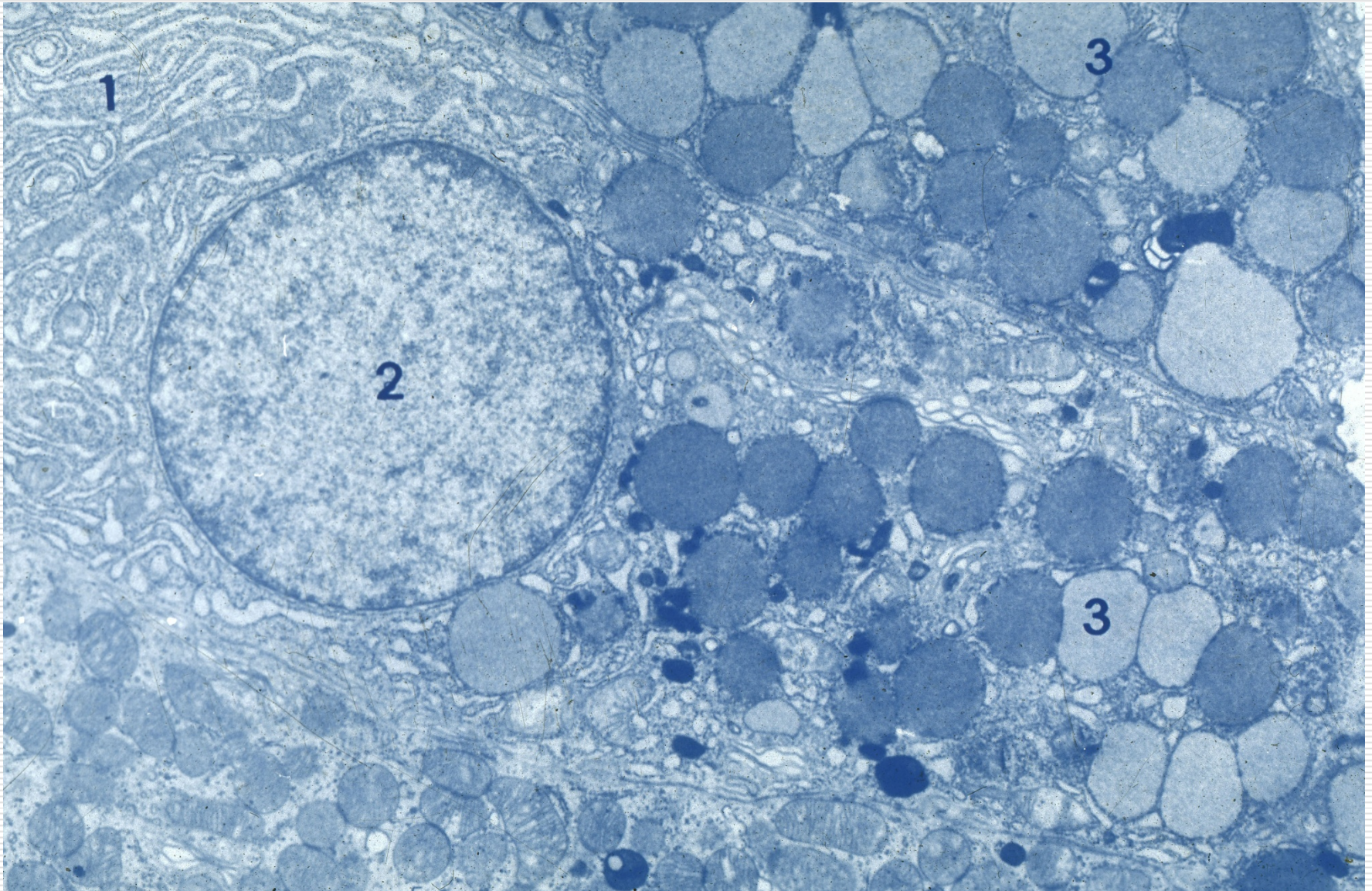


Capsule

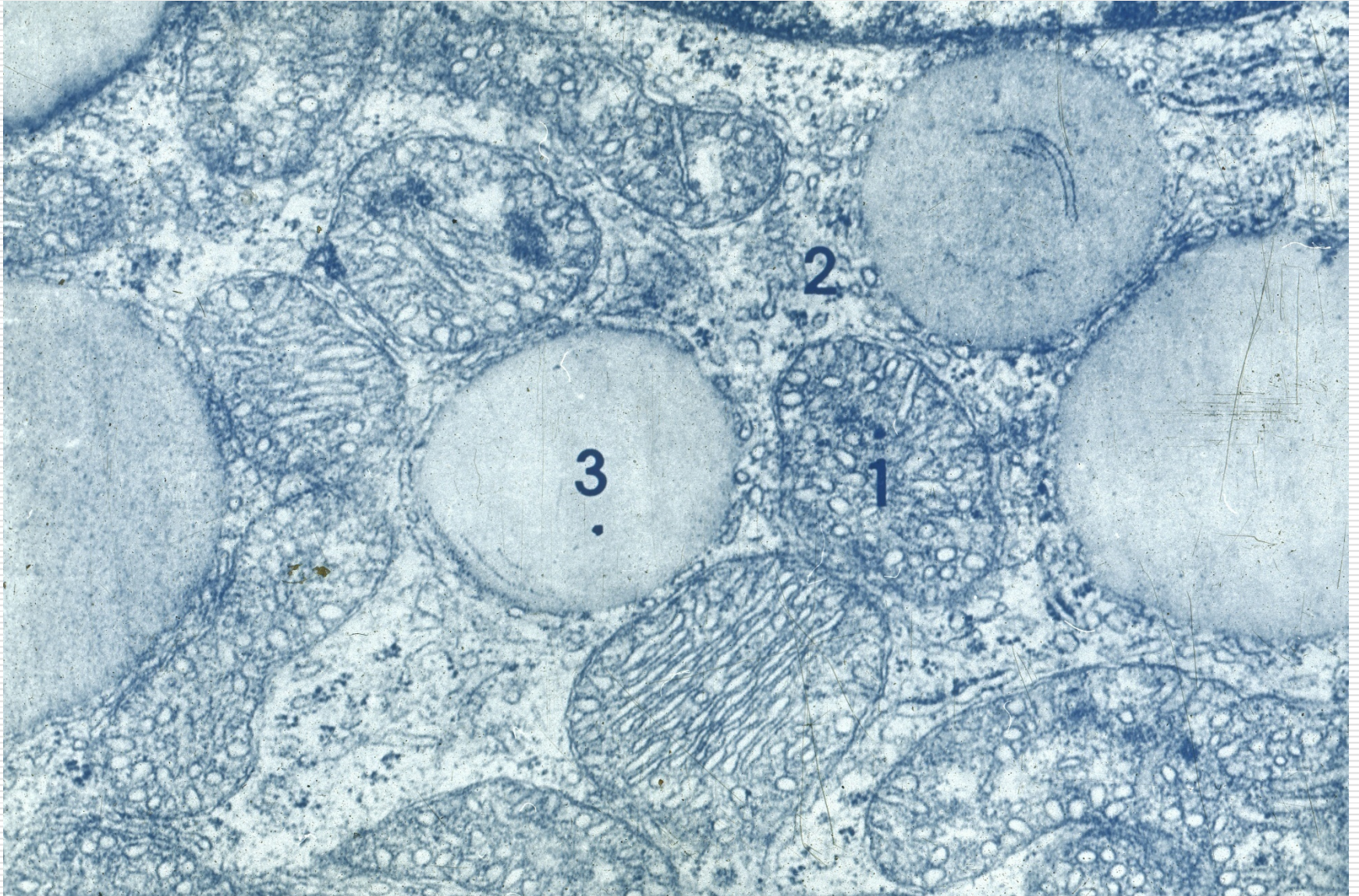




Protein-secreting cell

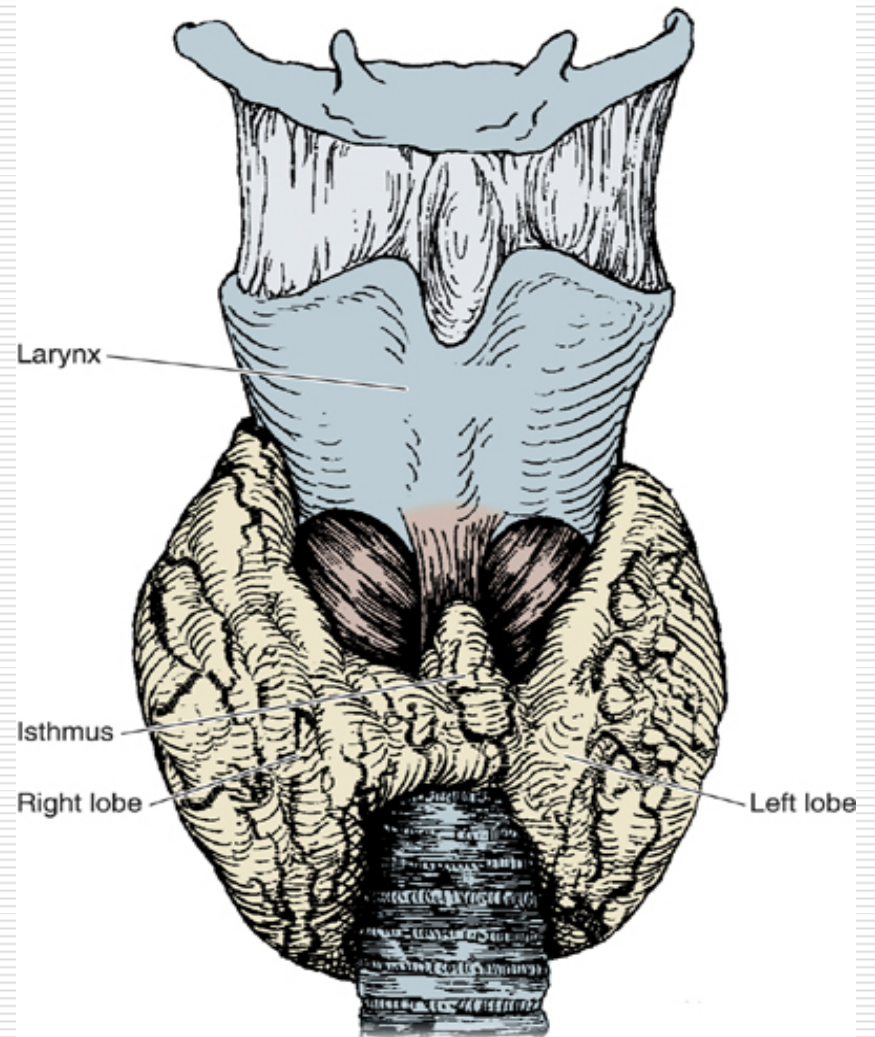


Steroid-secreting cell



Thyroid gland

- ❑ Structure
- ❑ Function



Structure of the thyroid gland

- Capsule

- Parenchyma

- Follicle

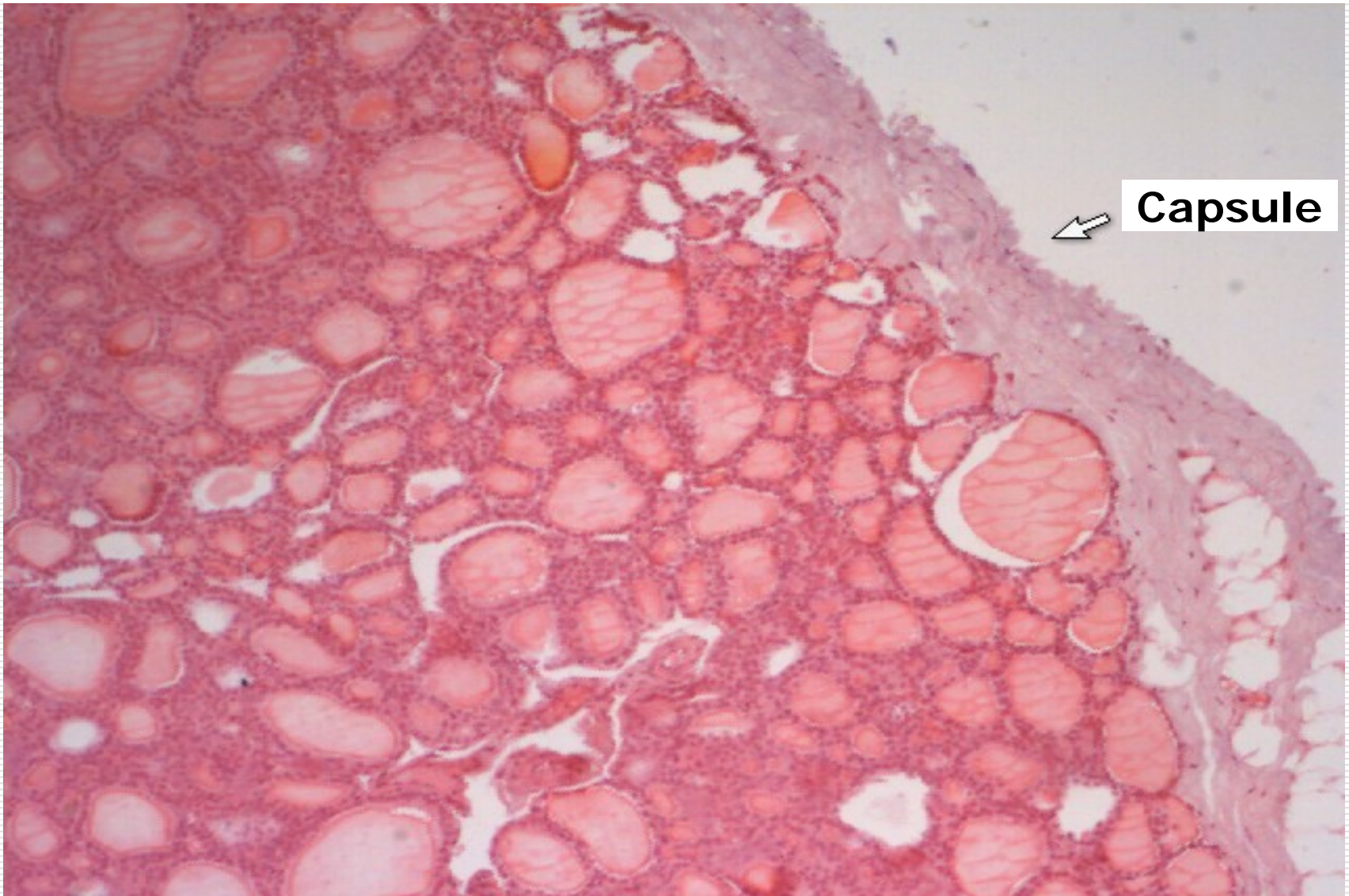
- Follicular epithelial cells

- Synthesize and release the thyroxine(T4) and triiodothyronine (T3)

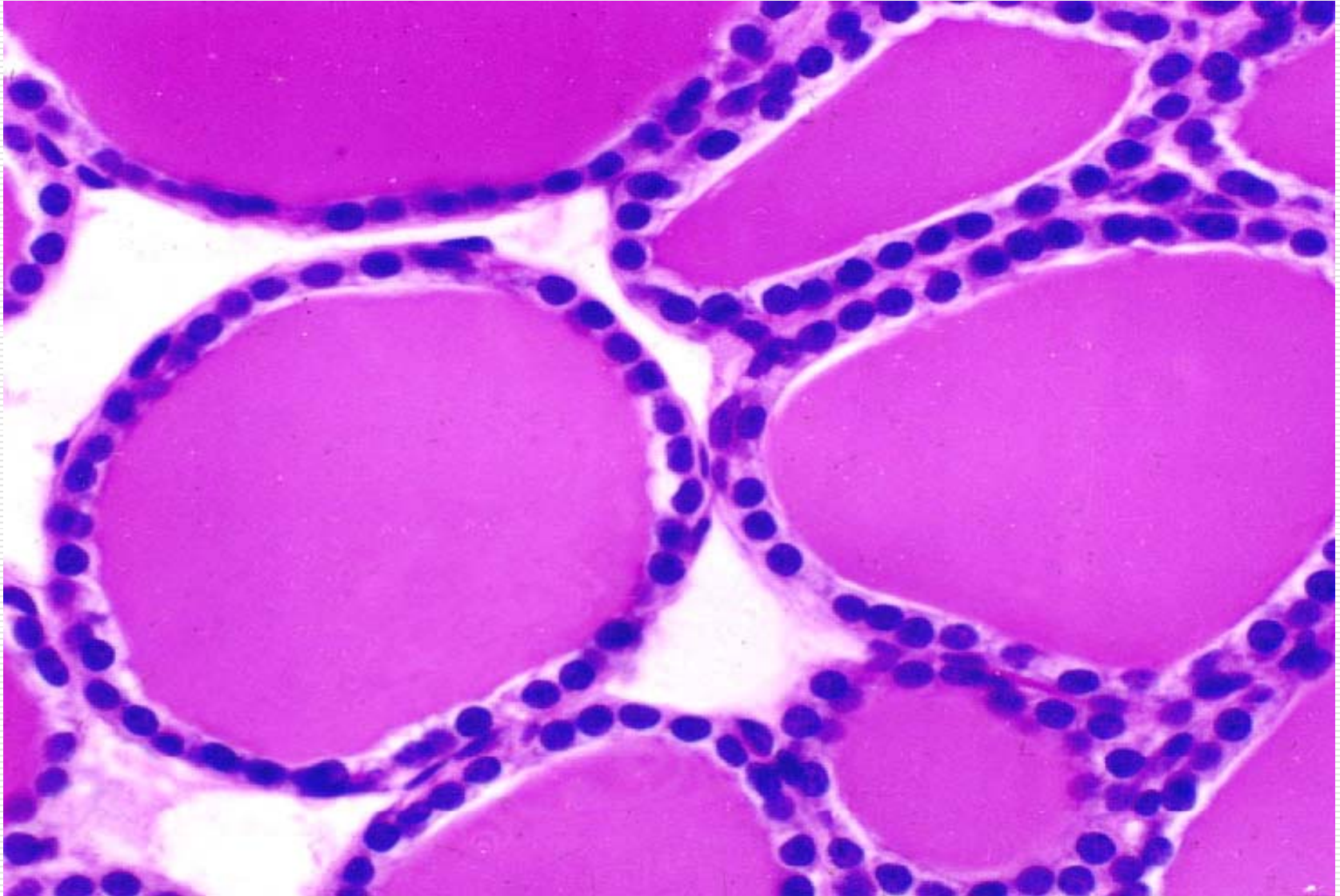
- Colloid: thyroglobulin

- Parafollicular (or calcitonin,C-) cell

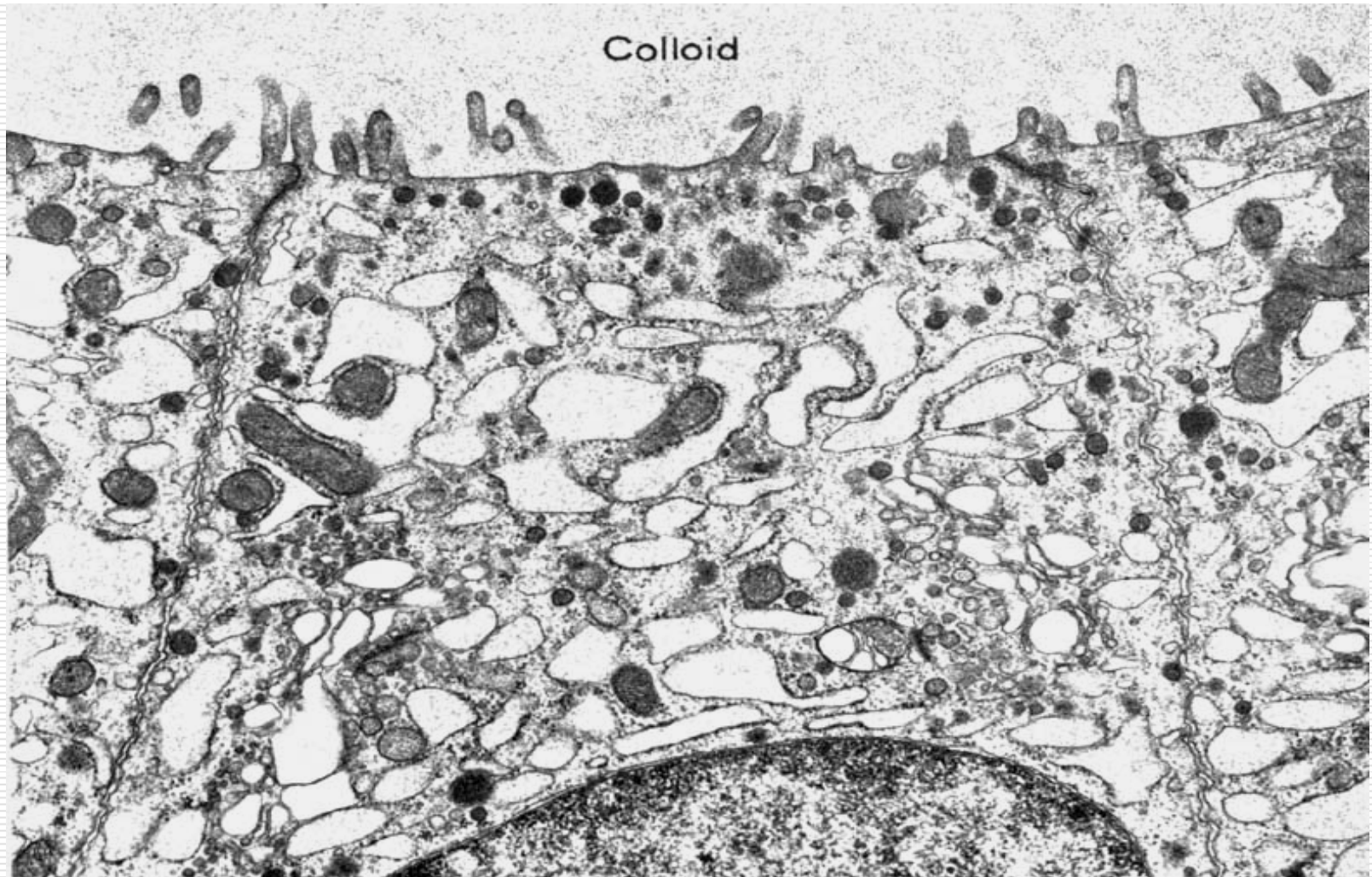
Thyroid gland



Thyroid gland

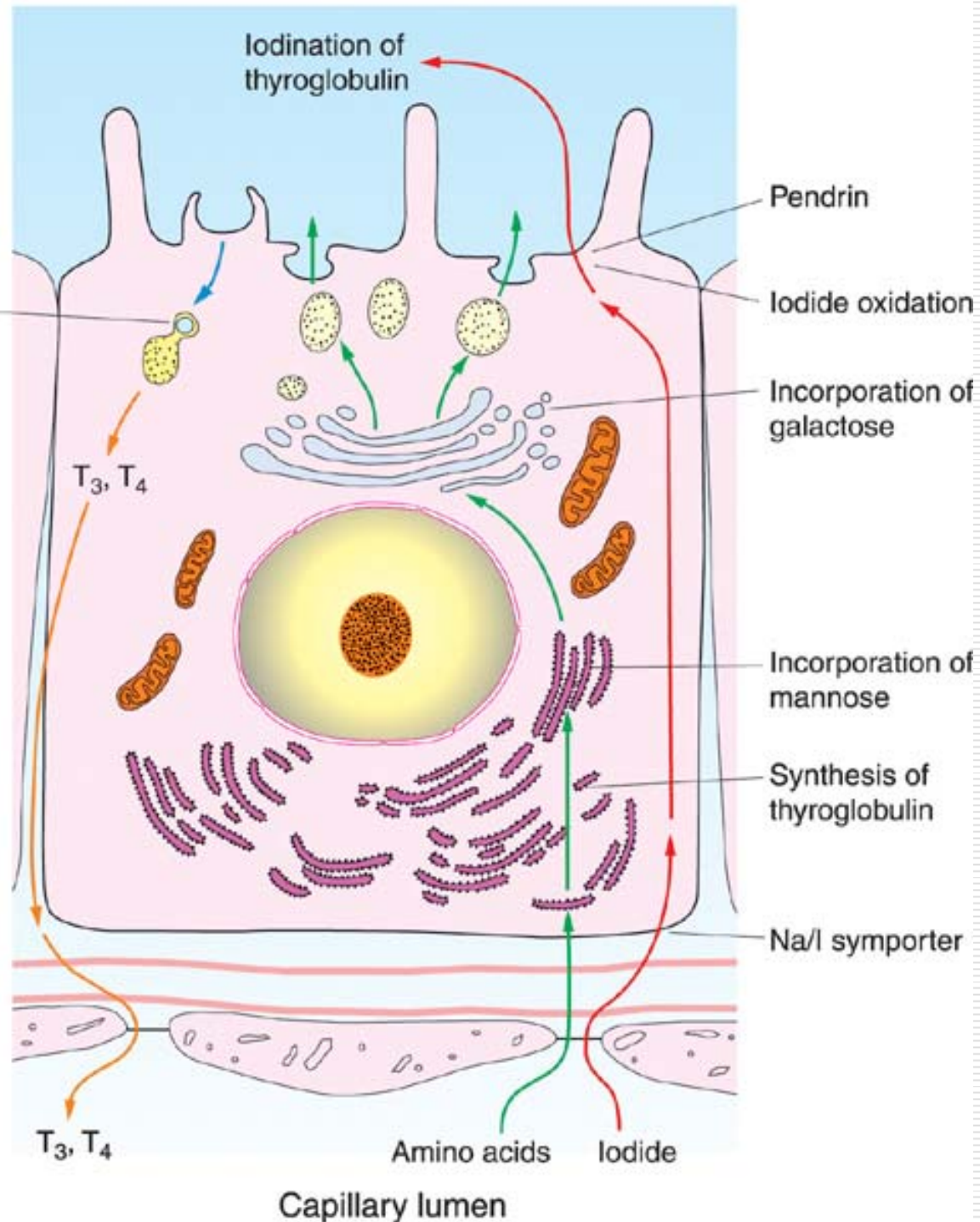


Follicular epithelial cell of the thyroid gland

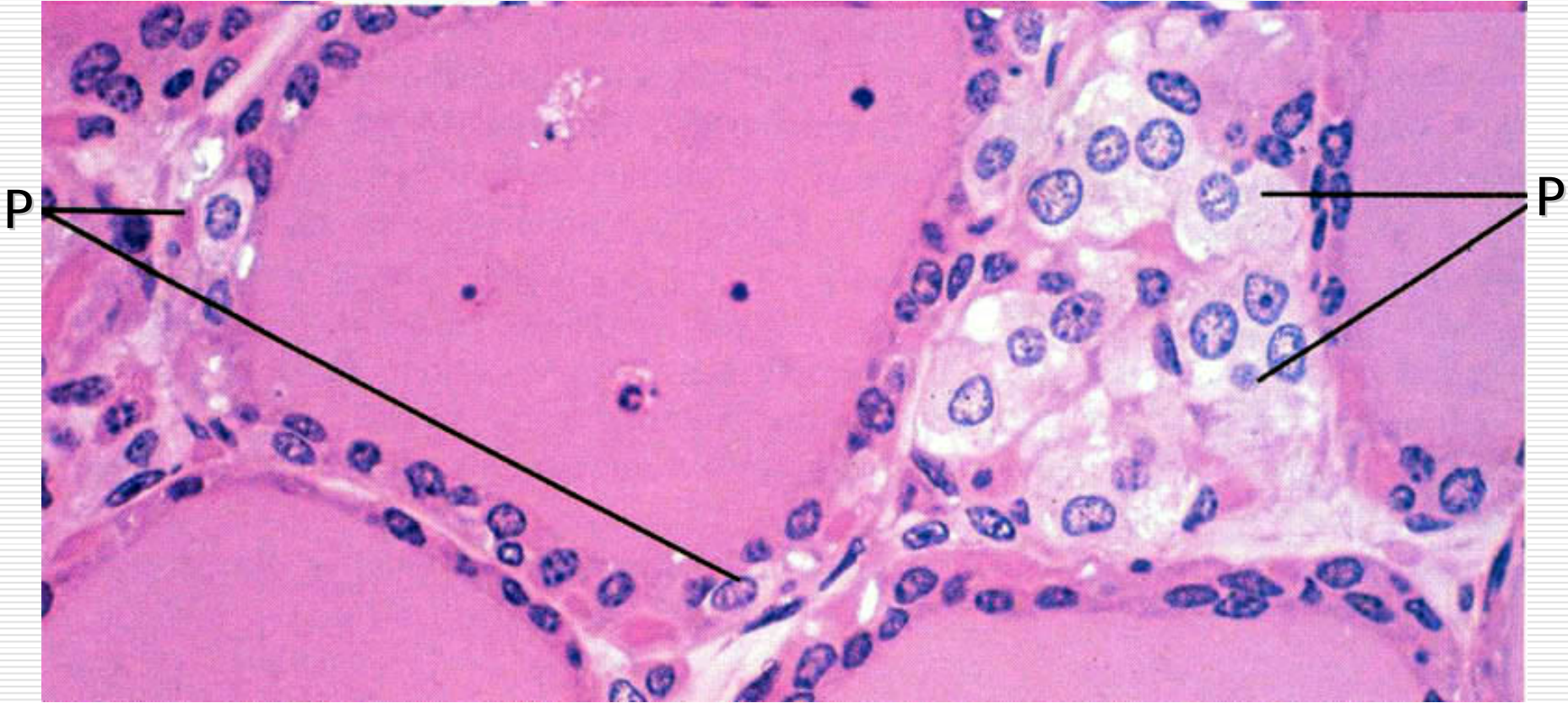


The processes of synthesis and secretion of thyroid hormones.

Digestion of thyroglobulin by lysosomal enzymes

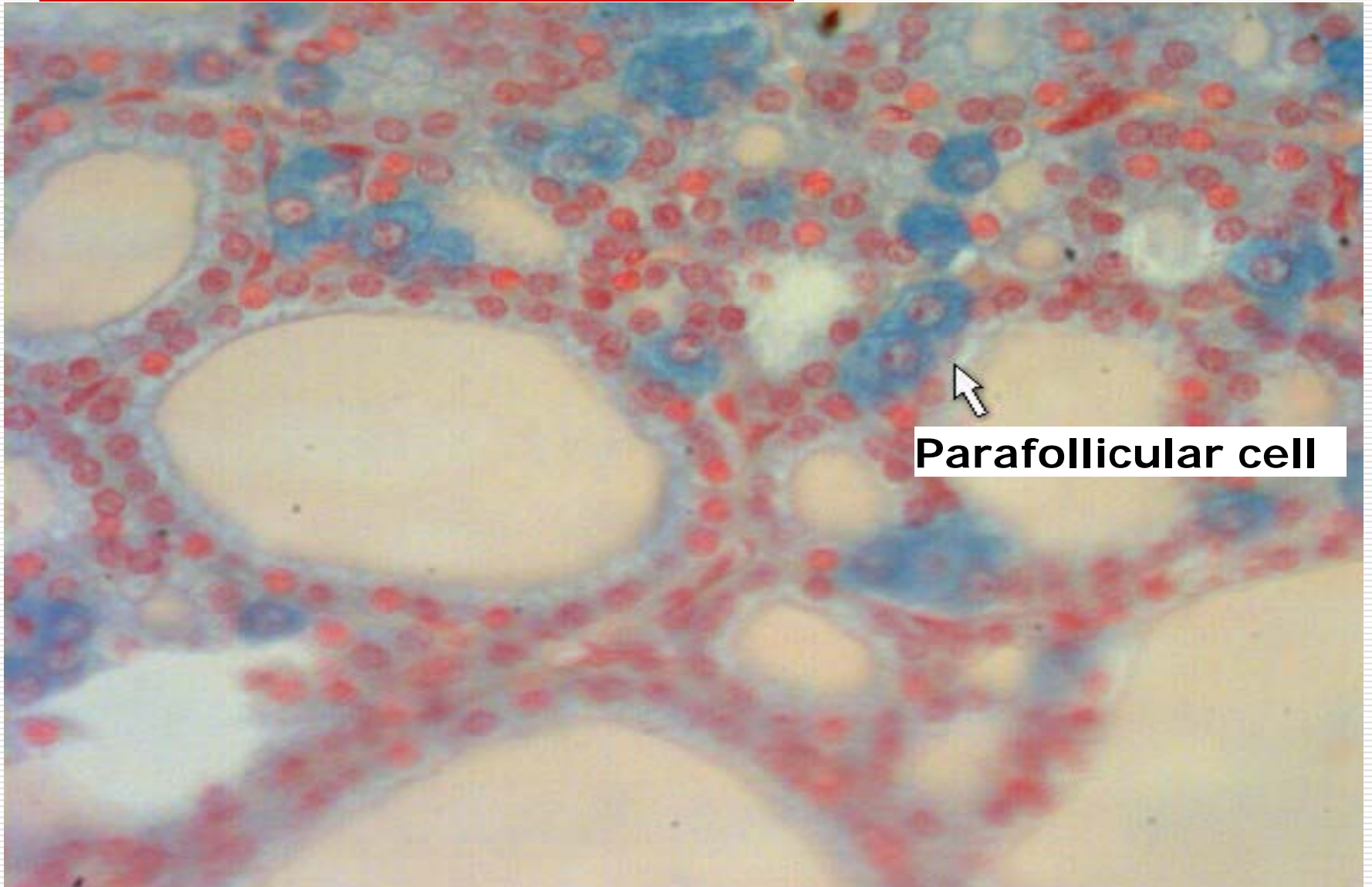


Thyroid gland



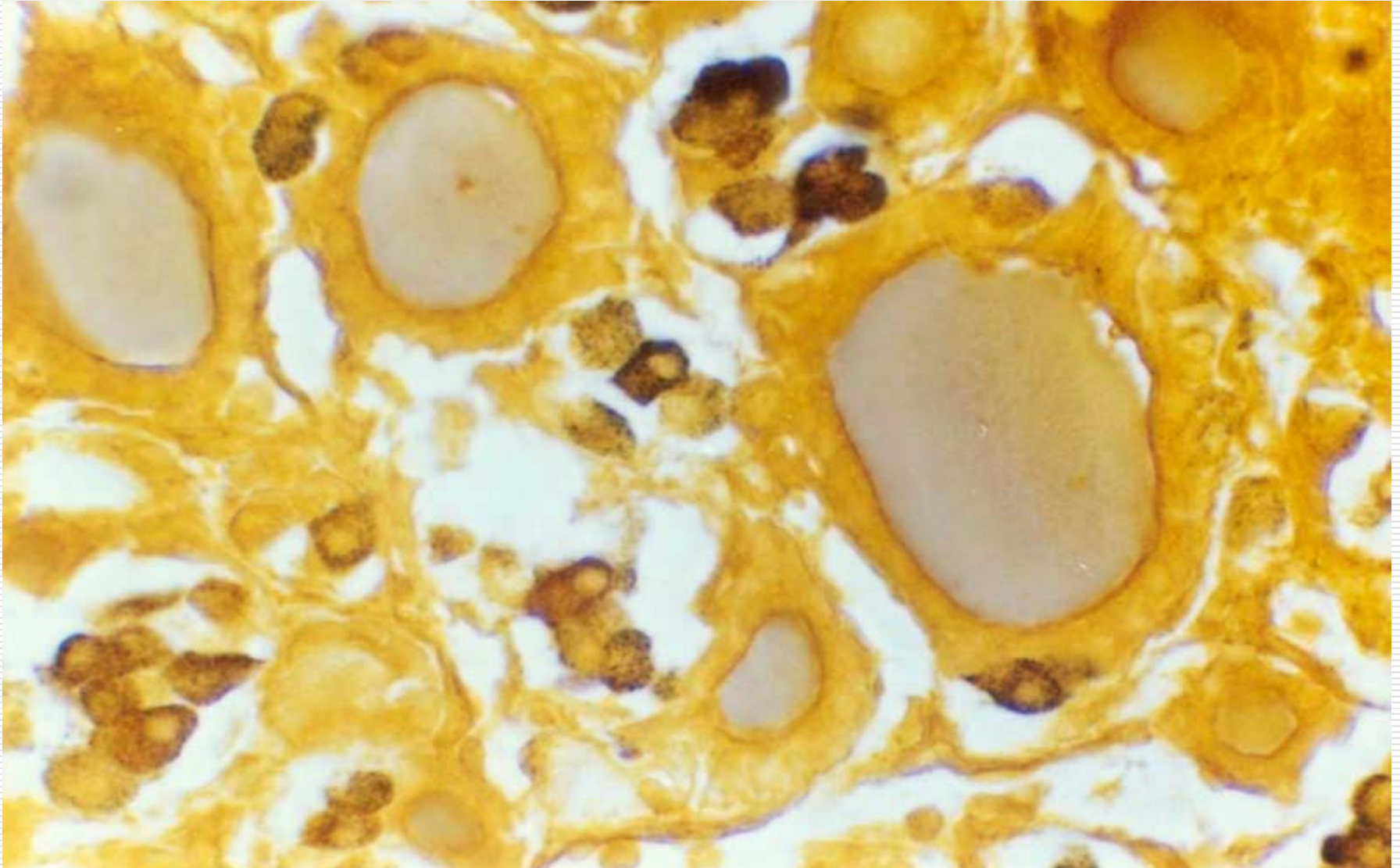
P: Parafollicular cell

Thyroid gland

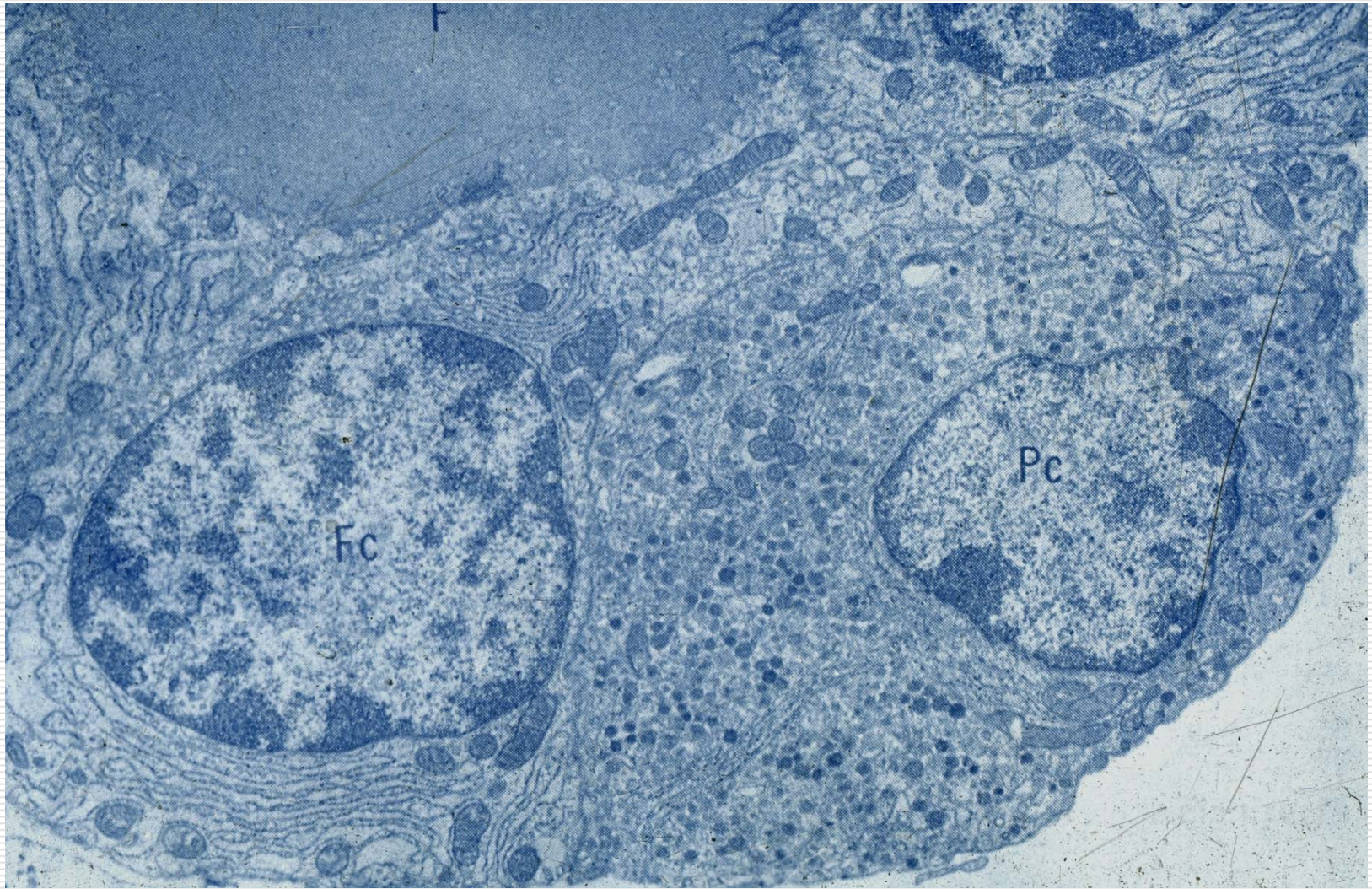


Parafollicular cell

Thyroid gland



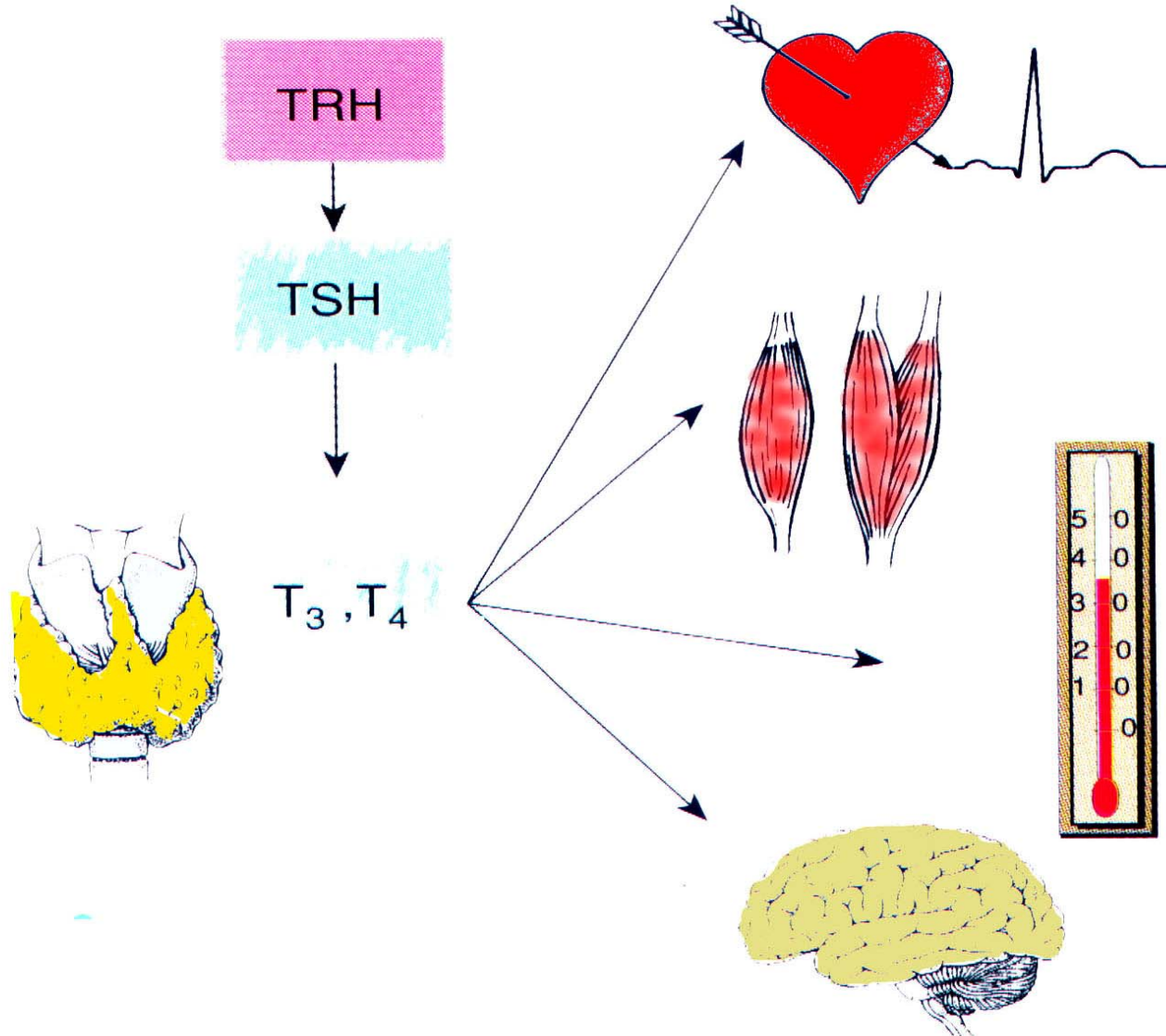
Thyroid gland



Fc: Follicular epithelial cell

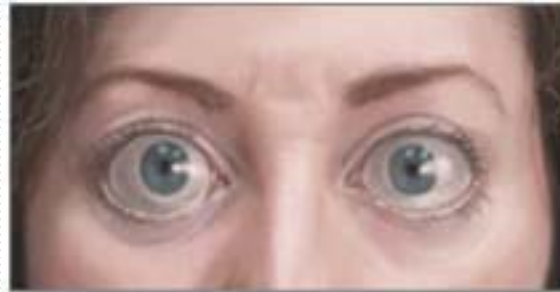Pc: Parafollicular cell

Function of the thyroid gland

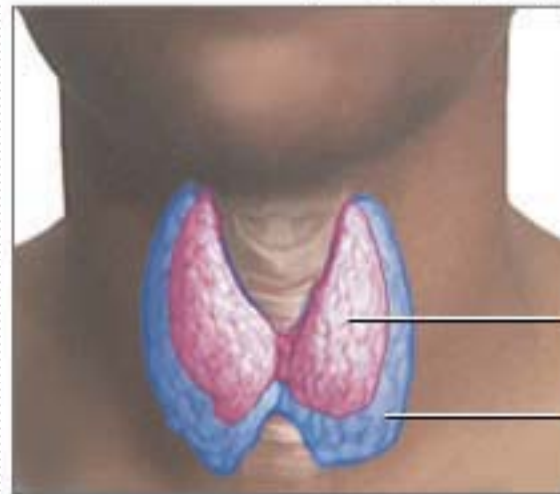


Thyroid disorders

- ❑ Hypothyroidism
 - Adult: myxedema
 - Child: cretinism
- ❑ Hyperthyroidism
 - Graves' disease



Exophthalmos (bulging eyes)



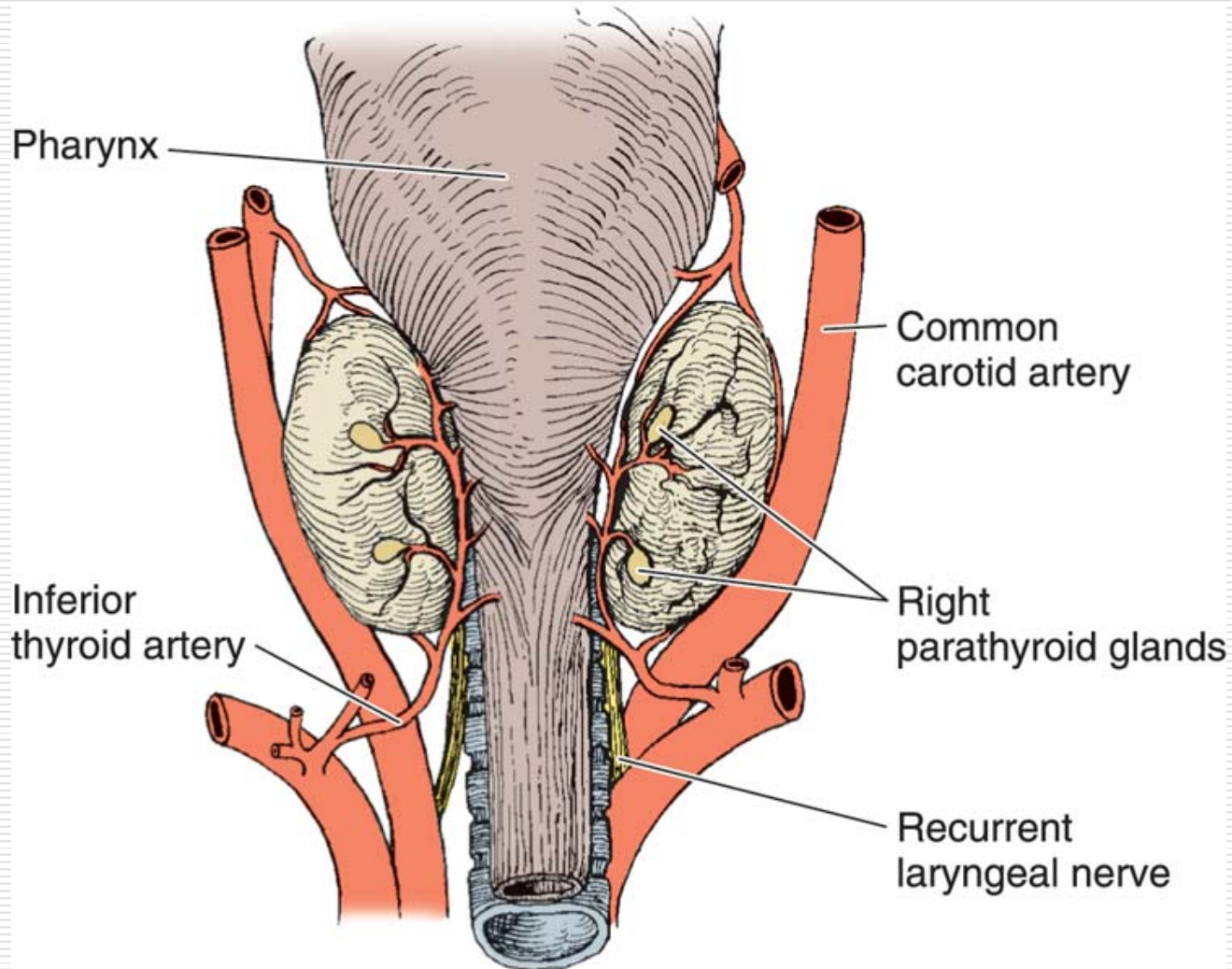
Normal thyroid

Enlarged thyroid

Diffuse goiter

Graves' disease

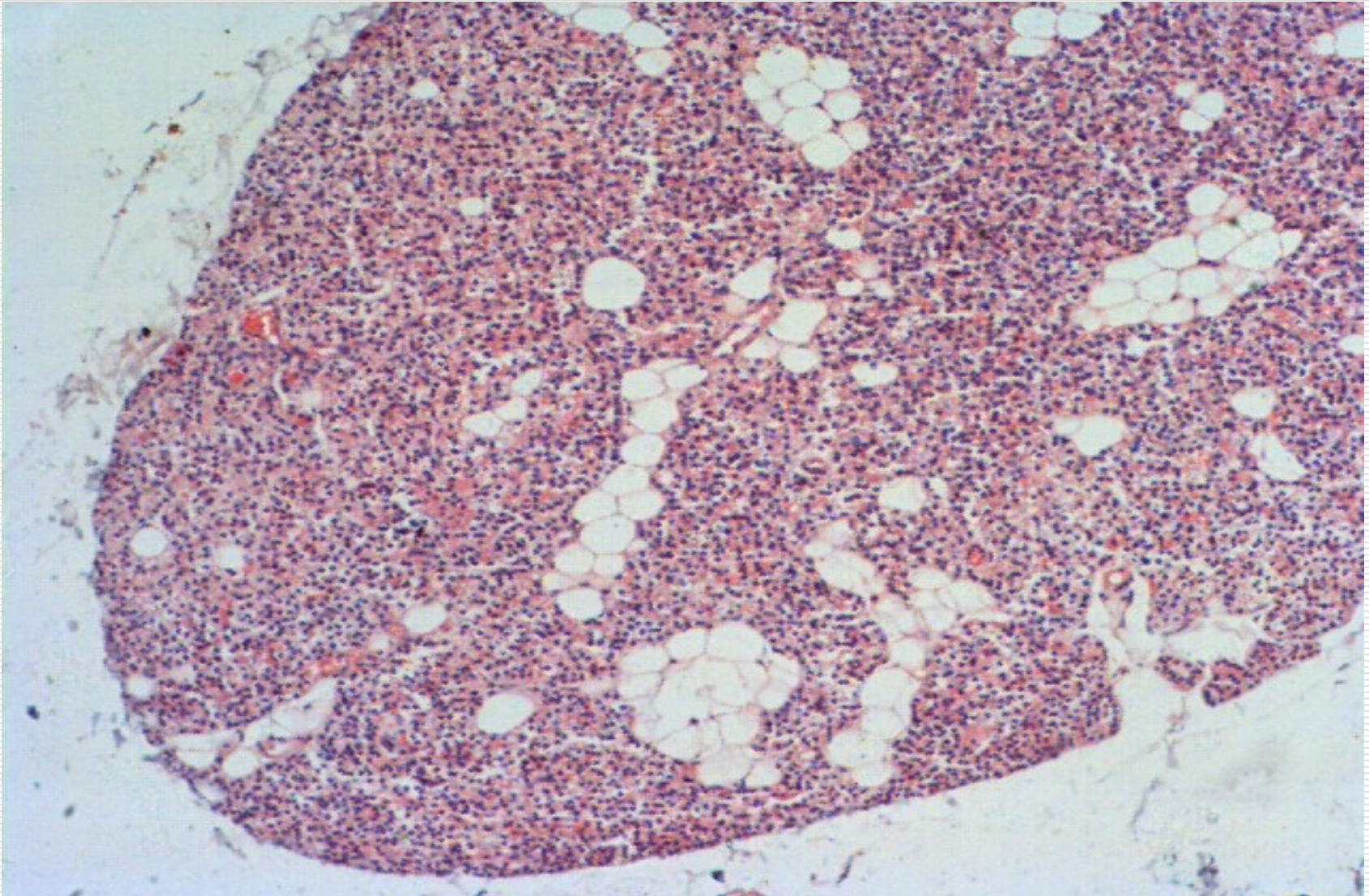
Parathyroid gland



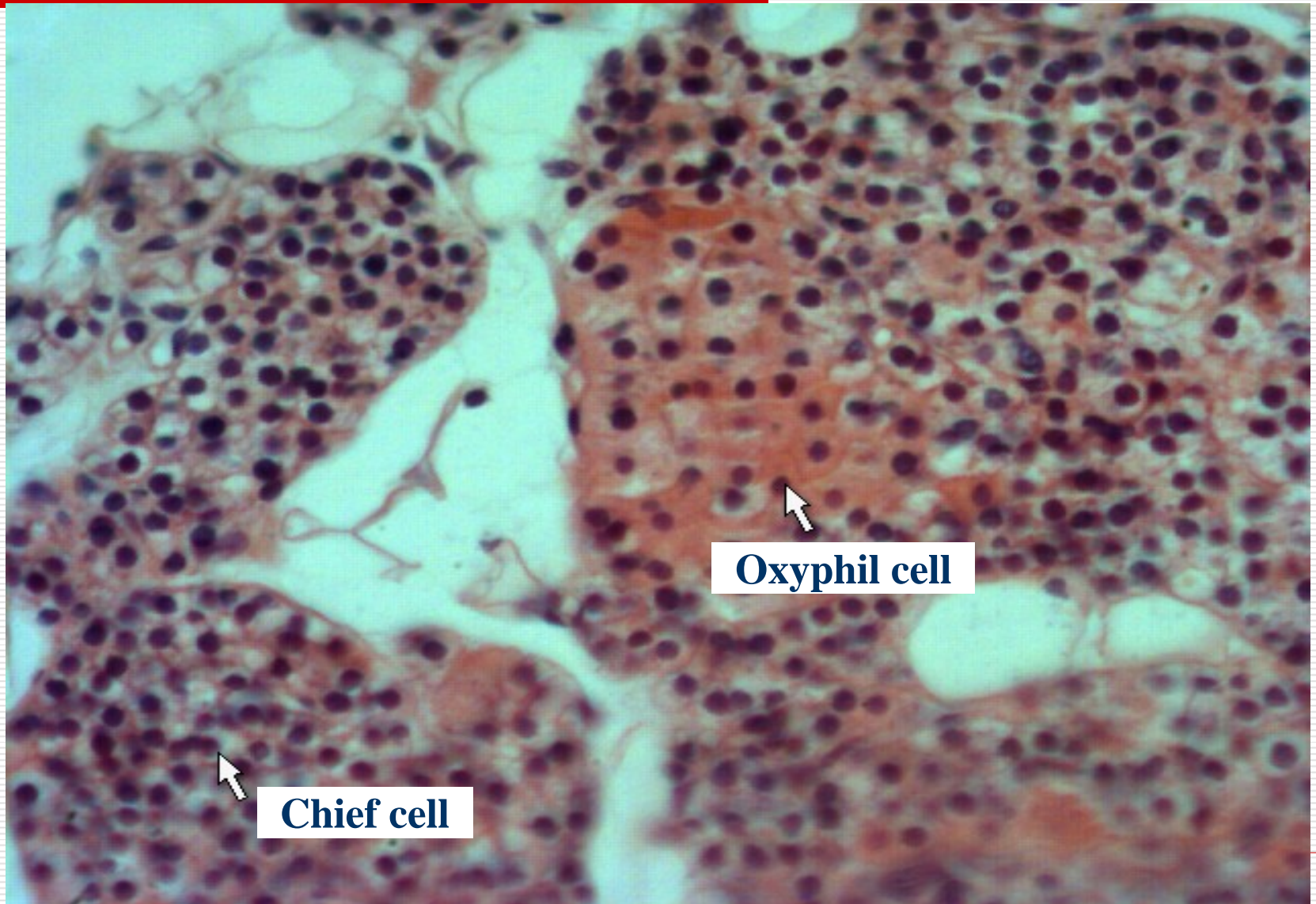
Structure of the parathyroid gland

- ❑ **Capsule**
 - ❑ **Parenchyma**
 - **Chief cell**
 - ❑ **Synthesize and secrete parathyroid hormone**
 - **Oxyphil (acidophilic) cell**
-

Parathyroid gland

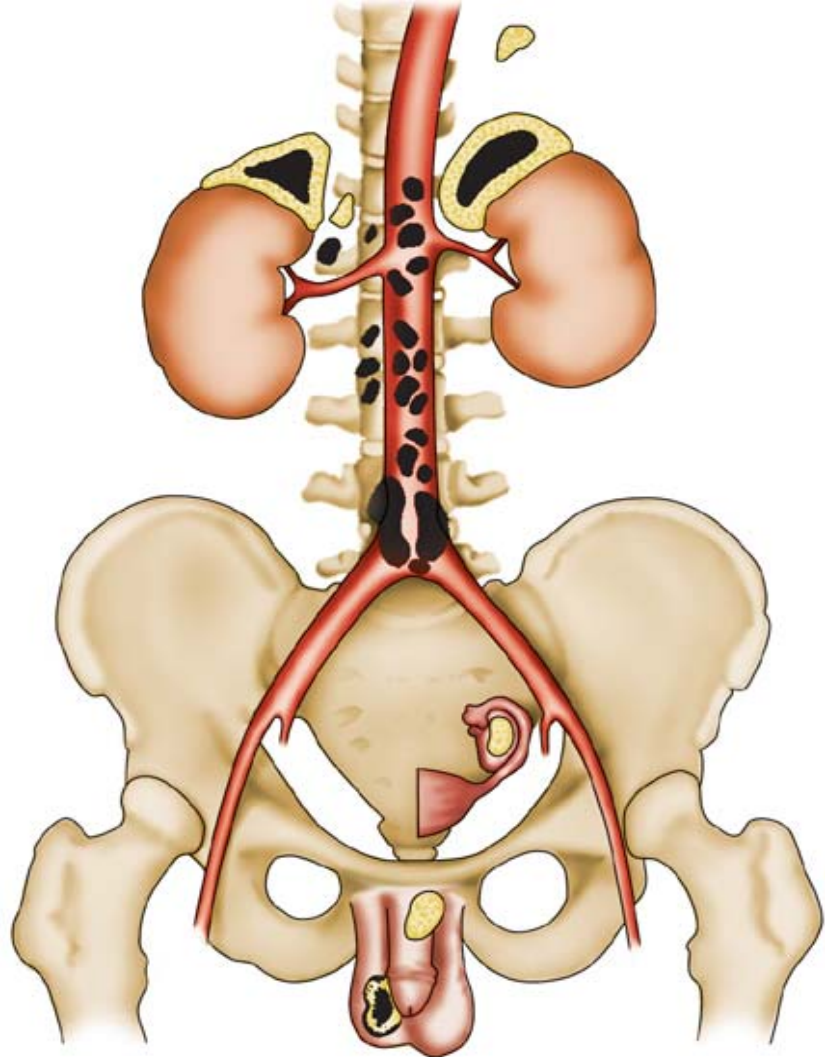


Parathyroid gland

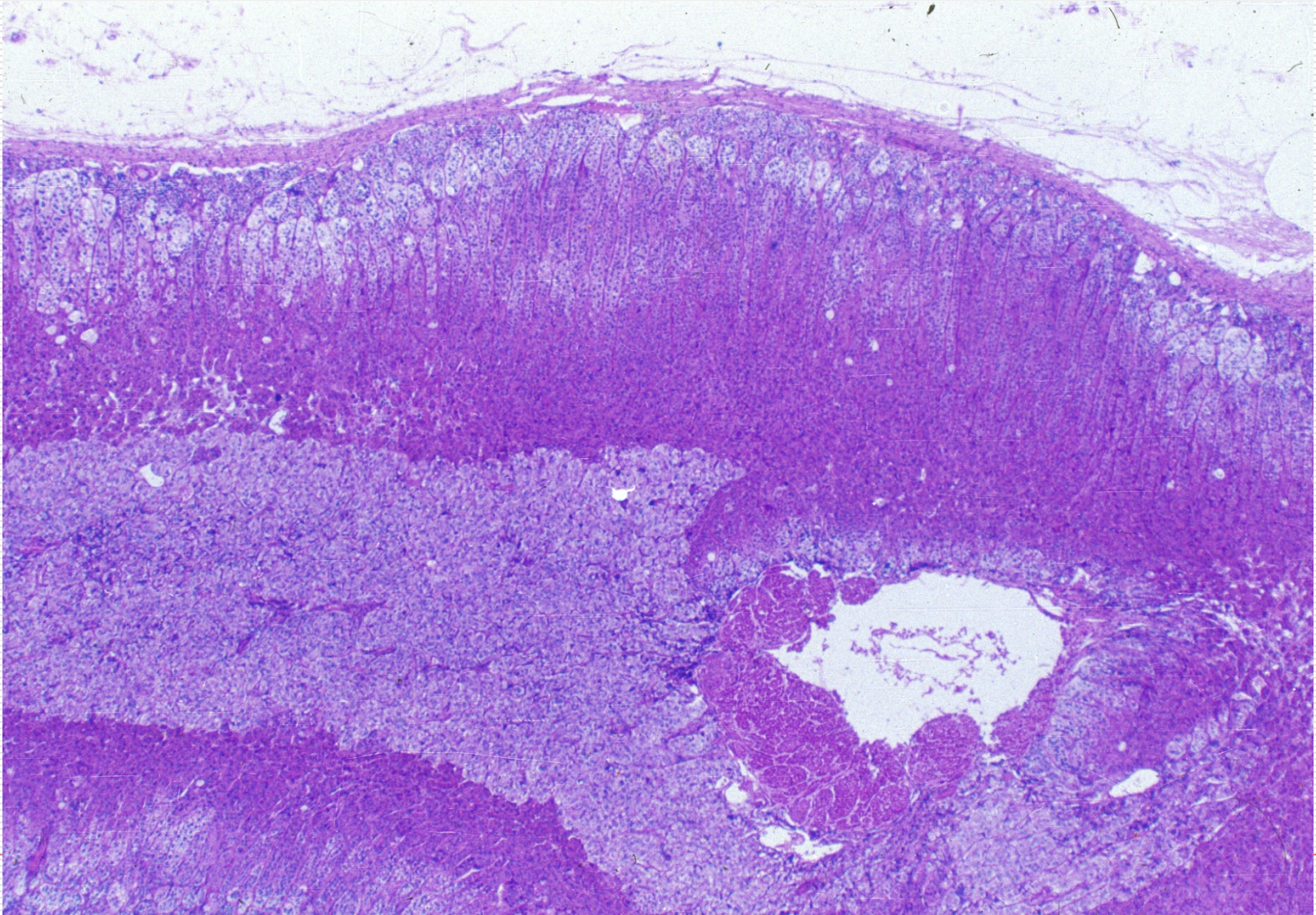


Adrenal gland

- ❑ Capsule
- ❑ Parenchyma
 - Adrenal cortex
 - Adrenal medulla



Adrenal gland



Adrenal cortex

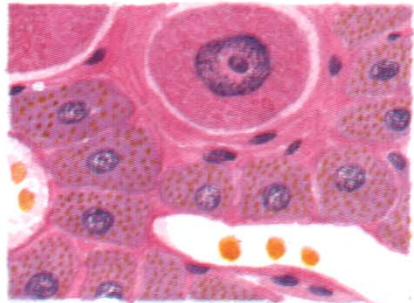
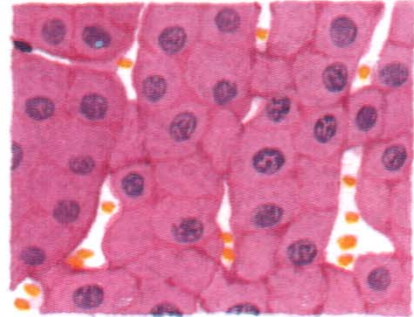
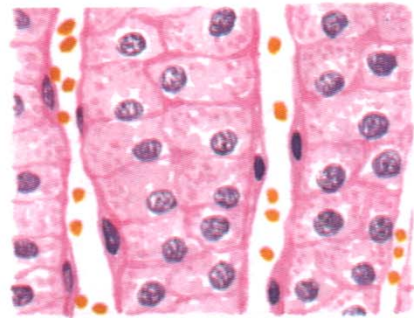
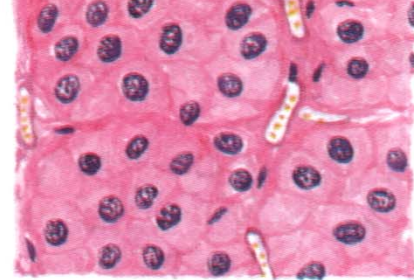
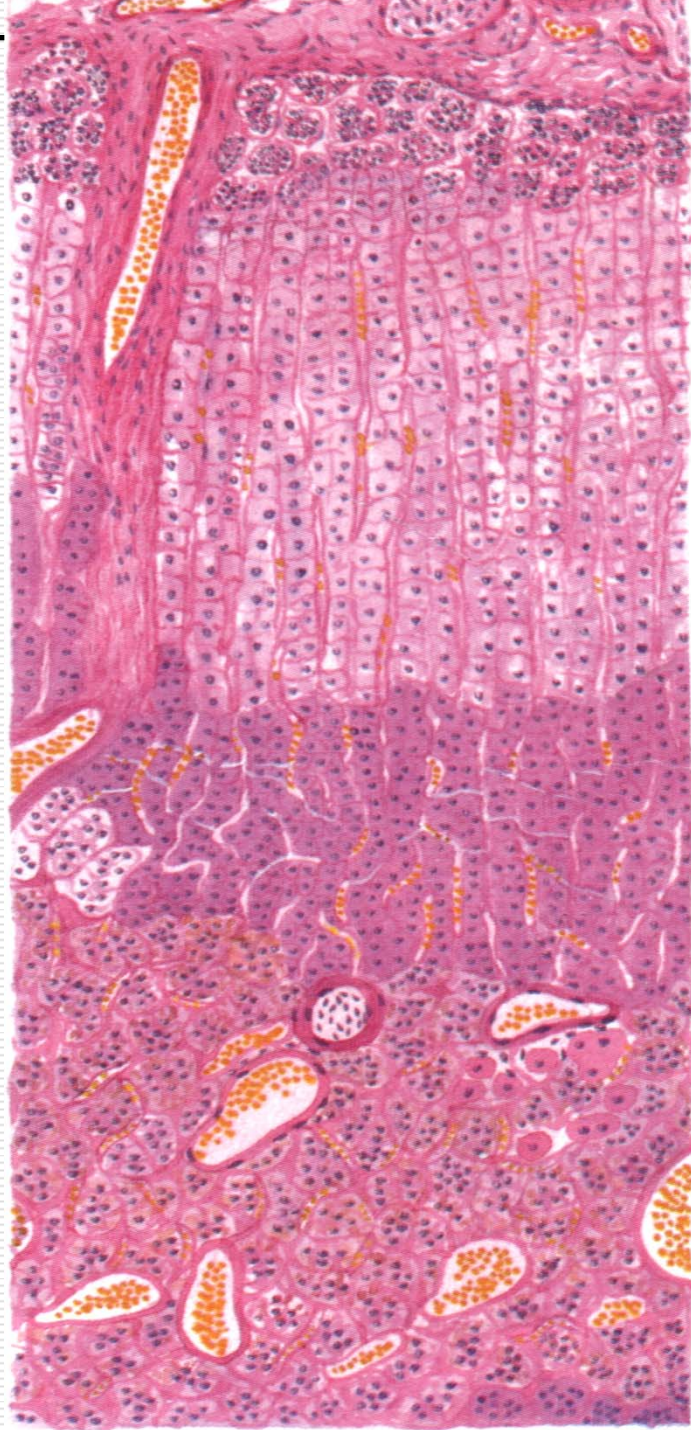
- ❑ Zona glomerulosa (5~10%)
 - Produce mineralocorticoid
 - ❑ Resorb sodium and excrete potassium
 - ❑ Zona fasciculata (70~80%)
 - Produce glucocorticoid
 - ❑ Regulate carbohydrate, protein and lipid metabolism
 - ❑ Influence the bone tissue
 - ❑ Impair inflammatory and immunological response
 - ❑ Zona reticularis (10~15%)
 - Produce glucocorticoid, androgen, estrogen
-

Capsule
Zona glomerulosa

Zona fasciculata

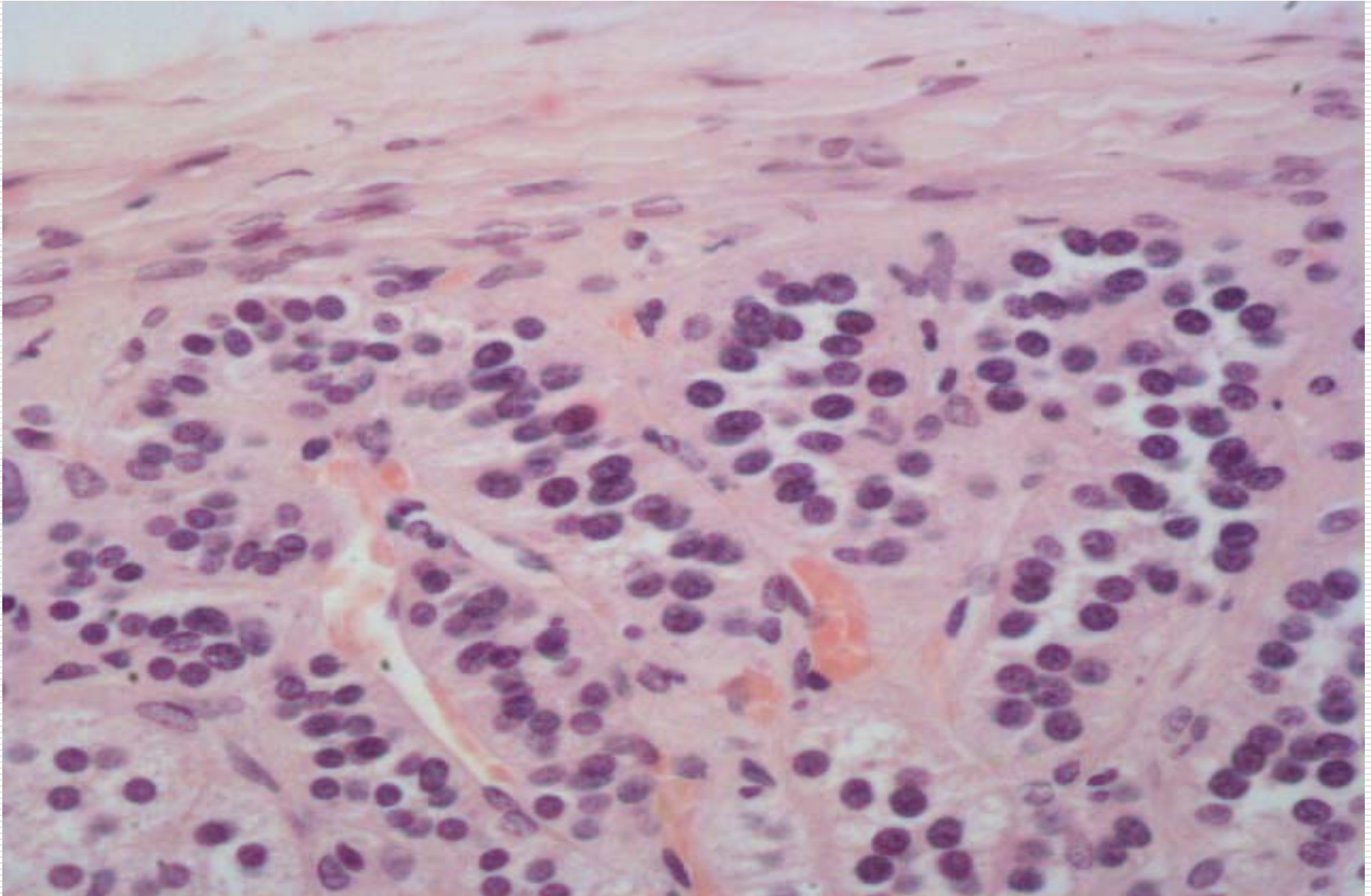
Zona reticularis

Medulla

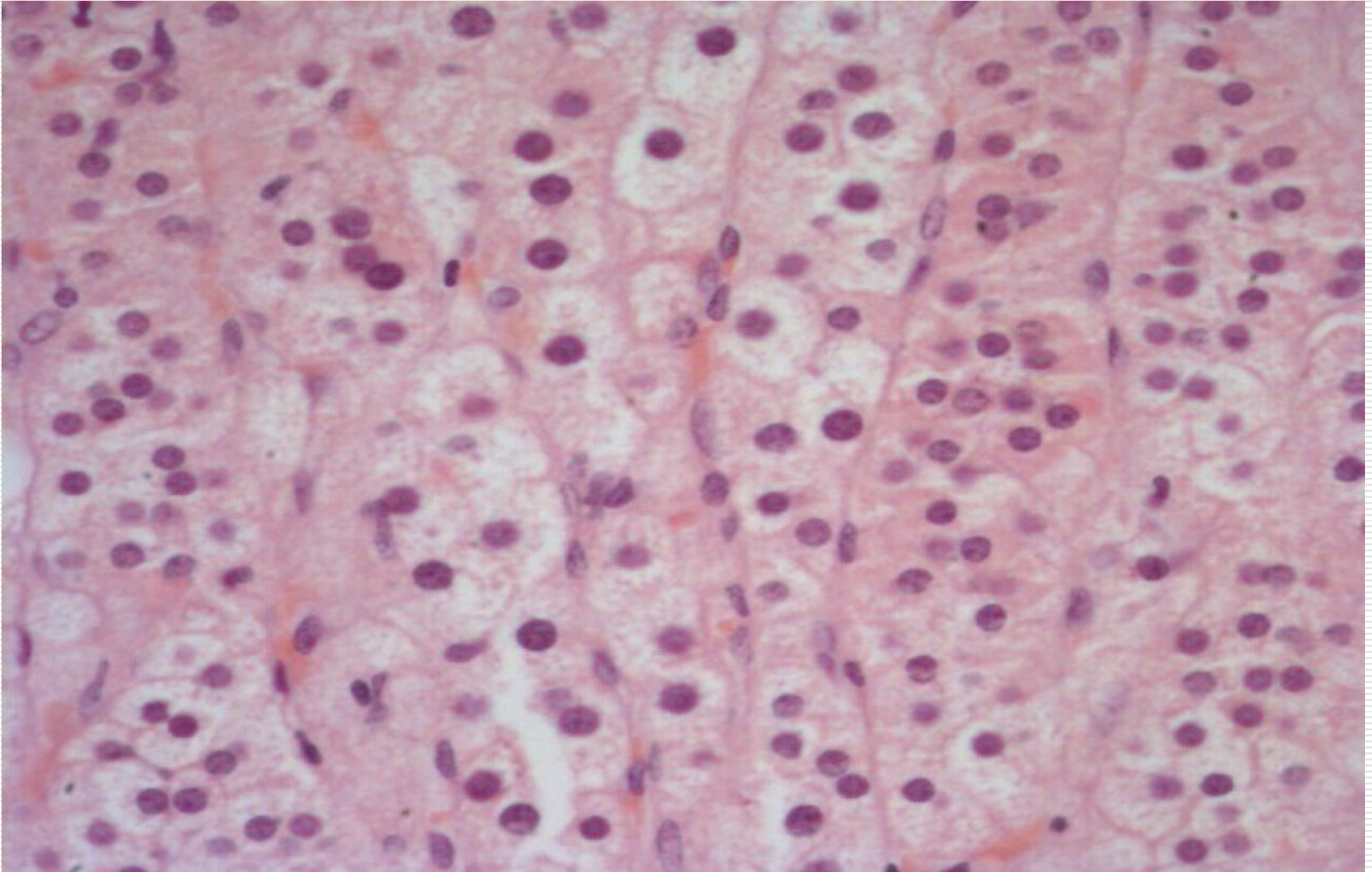


Adrenal gland

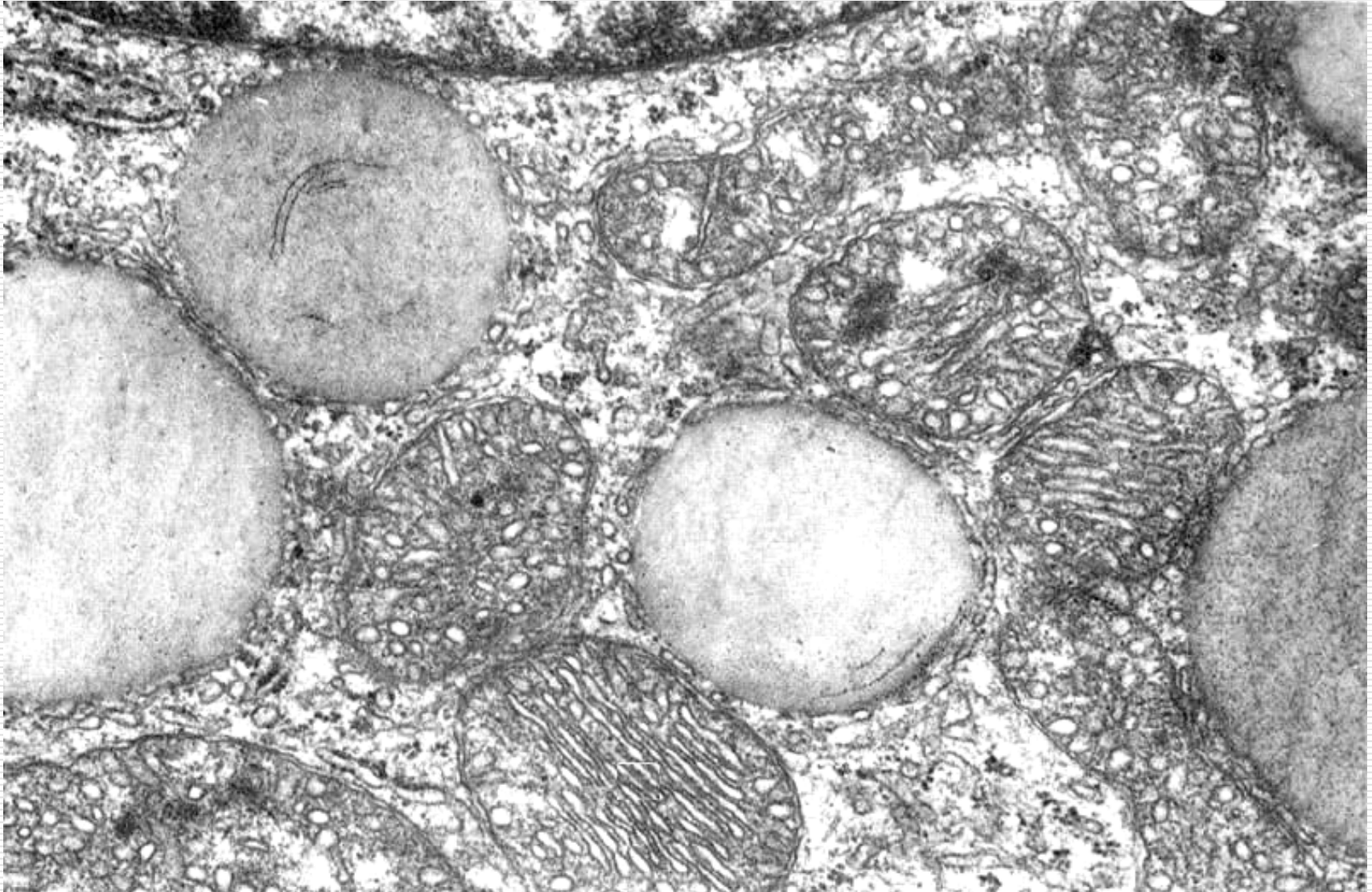
Zona glomerulosa of the adrenal cortex



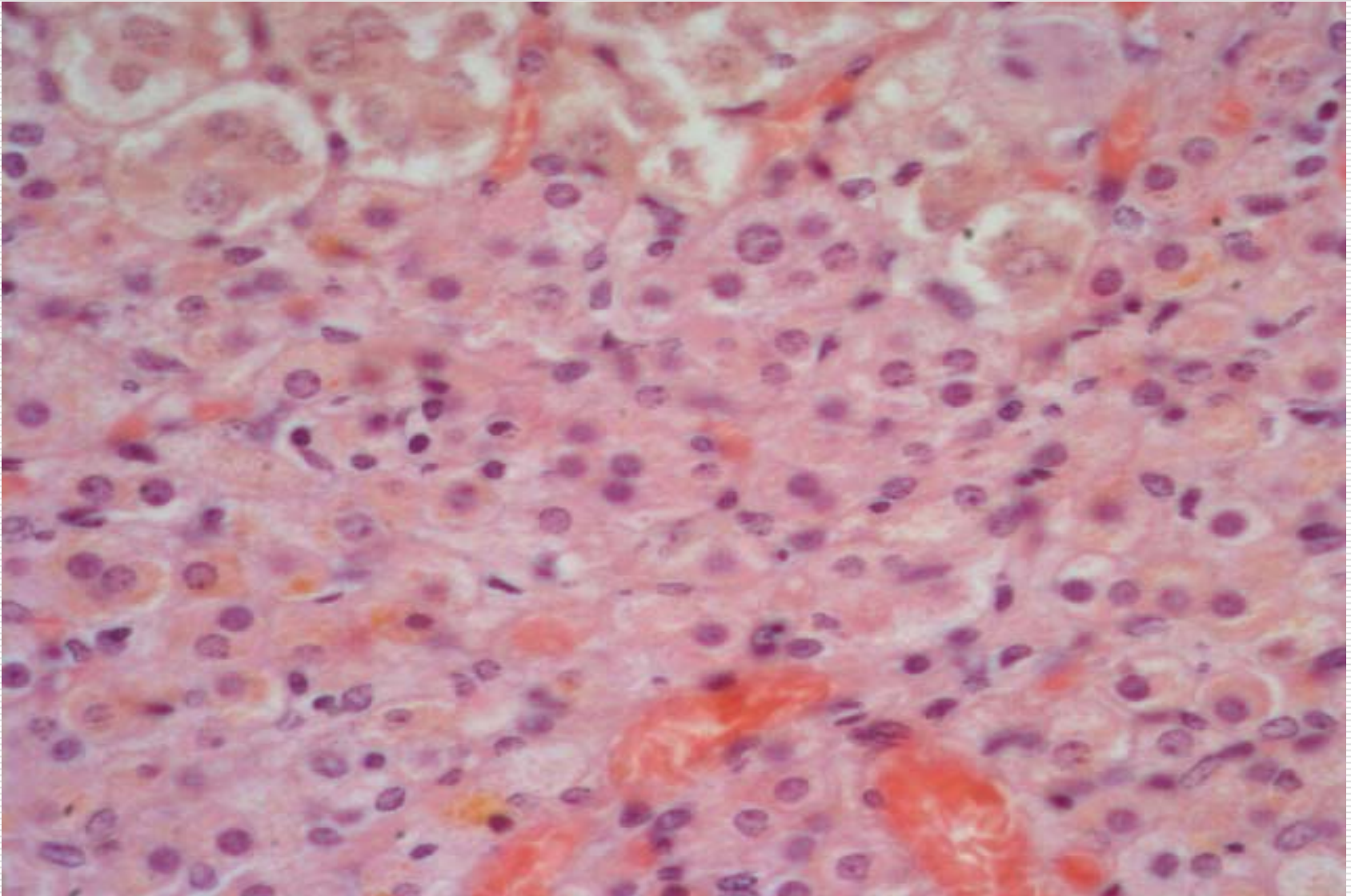
Zona fasciculata of the adrenal cortex



Steroid-secreting cell from zona fasciculata



Zona reticularis of the adrenal cortex



Adrenal medulla

Chromaffin cell

Adrenaline cell

- Epinephrine increases the heart rate and dilates blood vessels to cardiac and skeletal muscles, and also dilates the bronchioles.

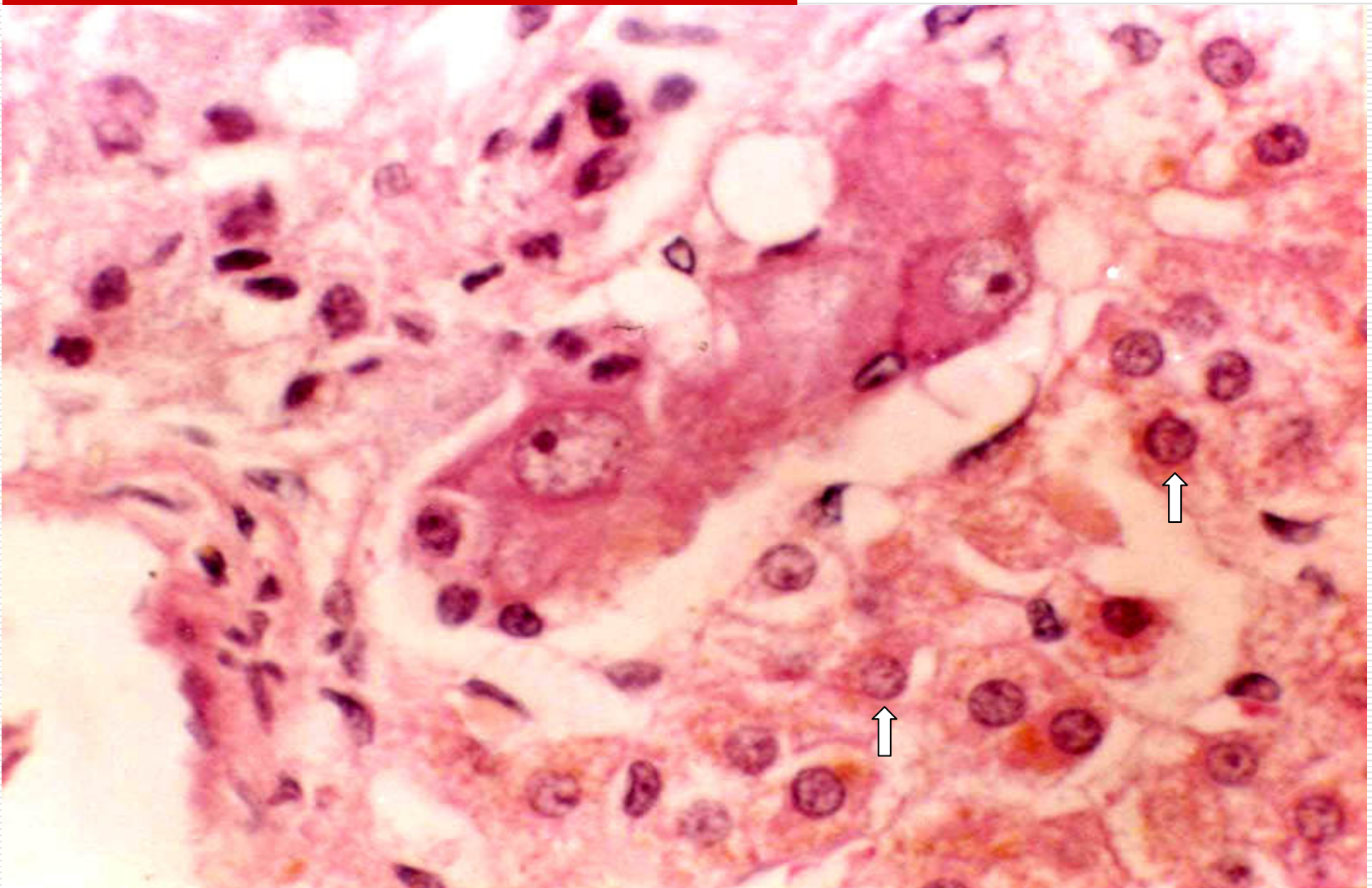
Noradrenaline cell

- Norepinephrine increases the blood pressure and blood flow to the heart, brain and skeletal muscles.

Sympathetic ganglion cell

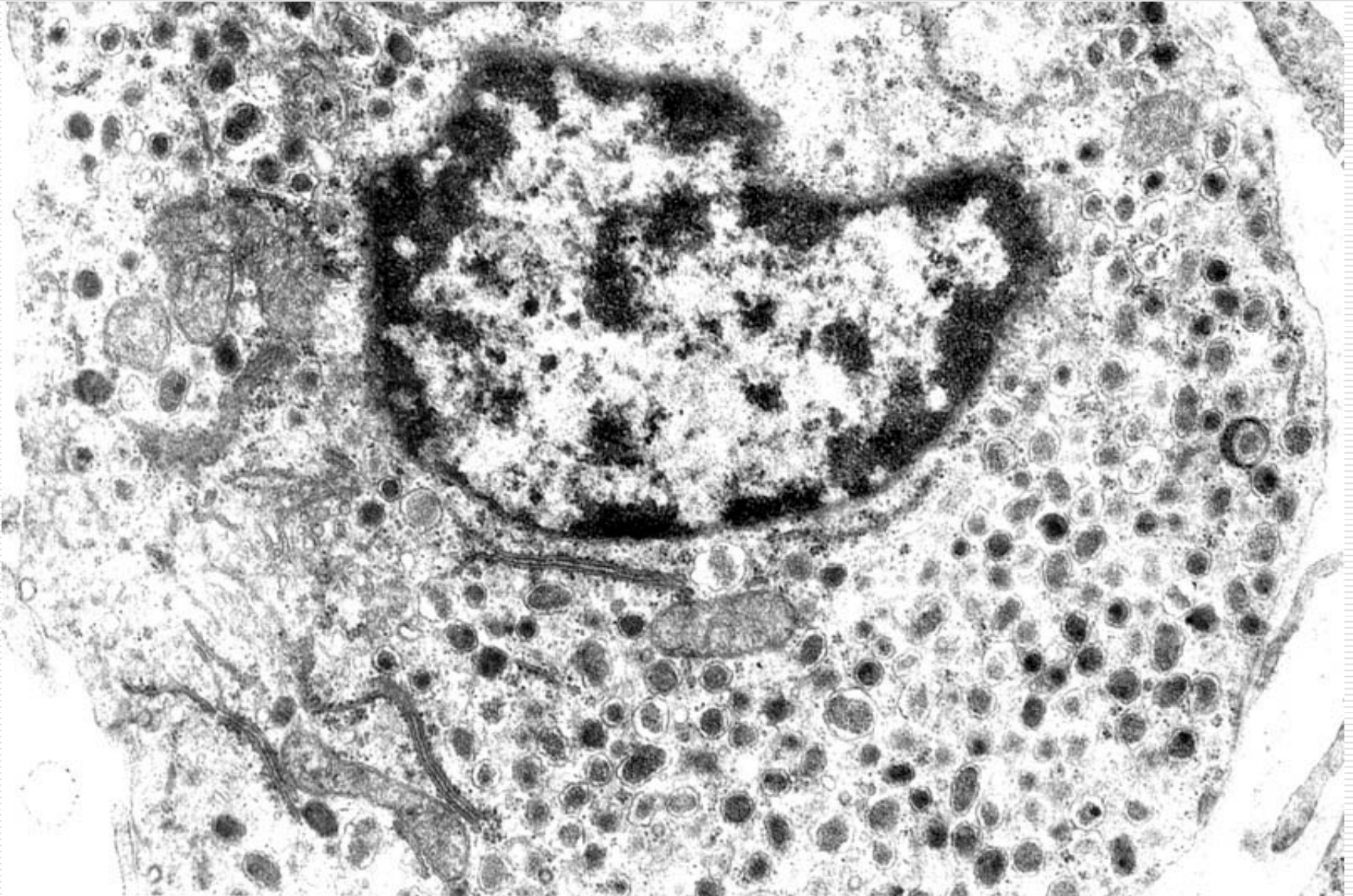
Centre vein

Adrenal medulla

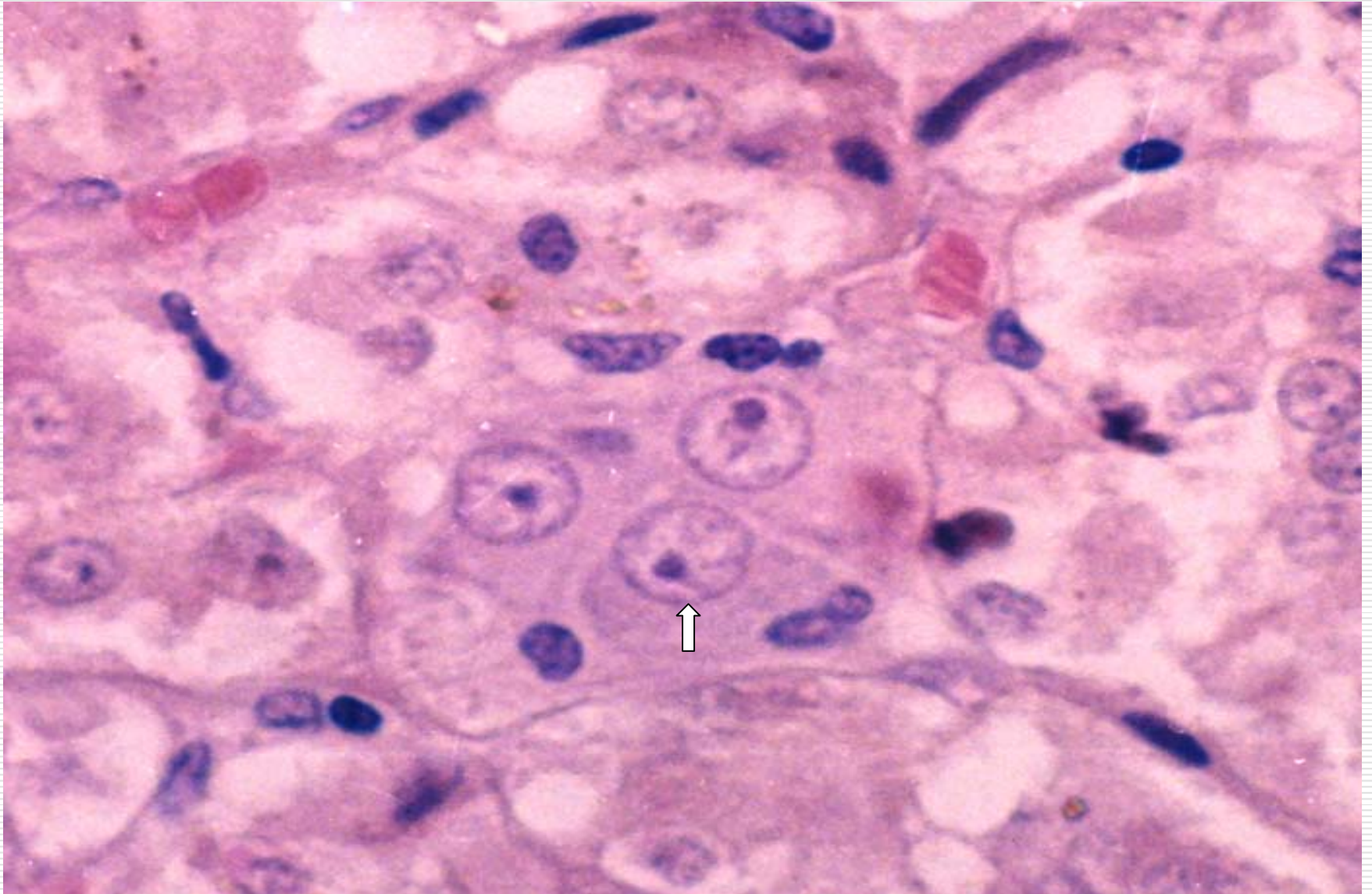


Chromaffin cell

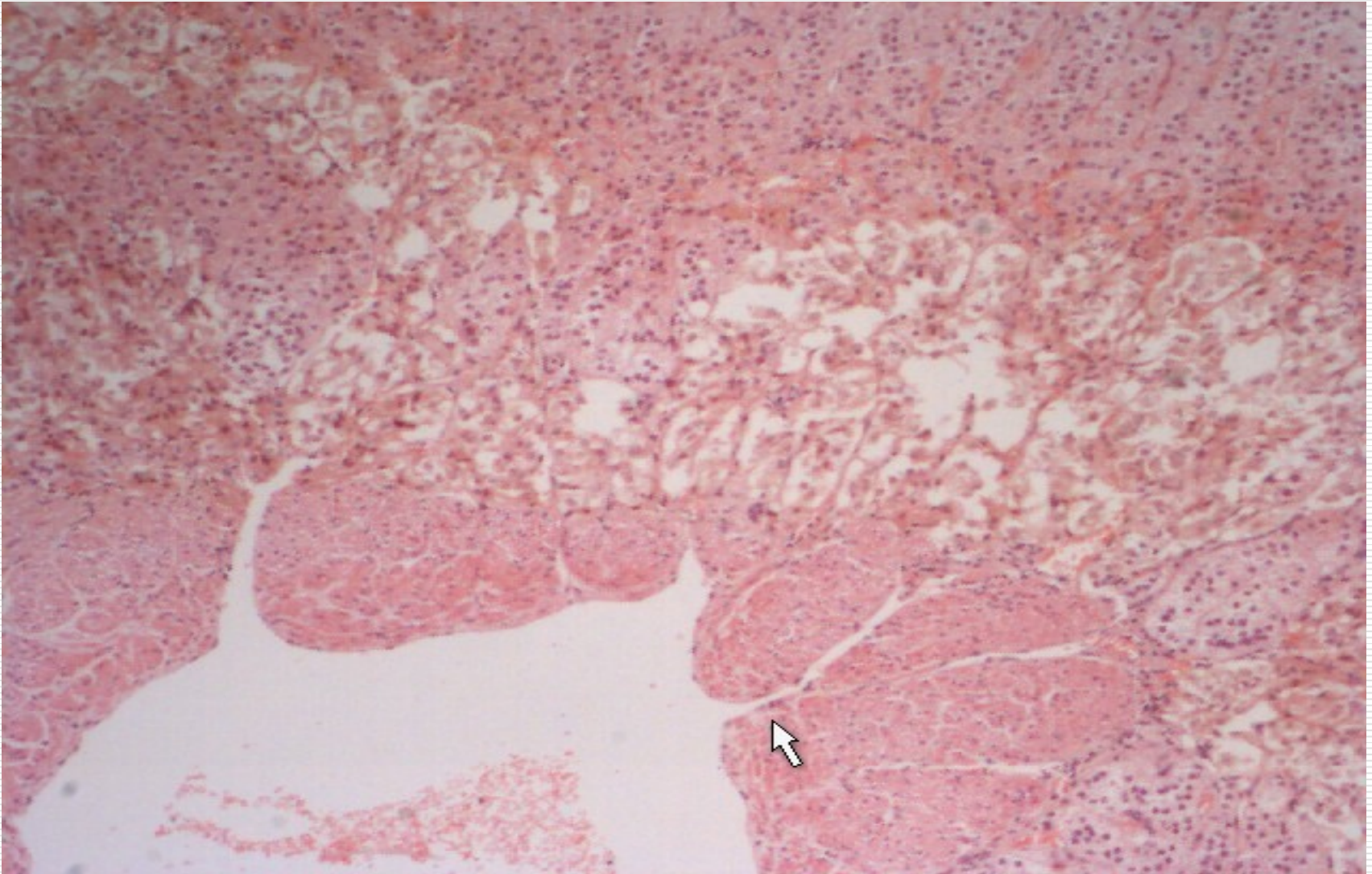
Adrenaline cell of the adrenal medulla



Sympathetic ganglion cell of the adrenal medulla

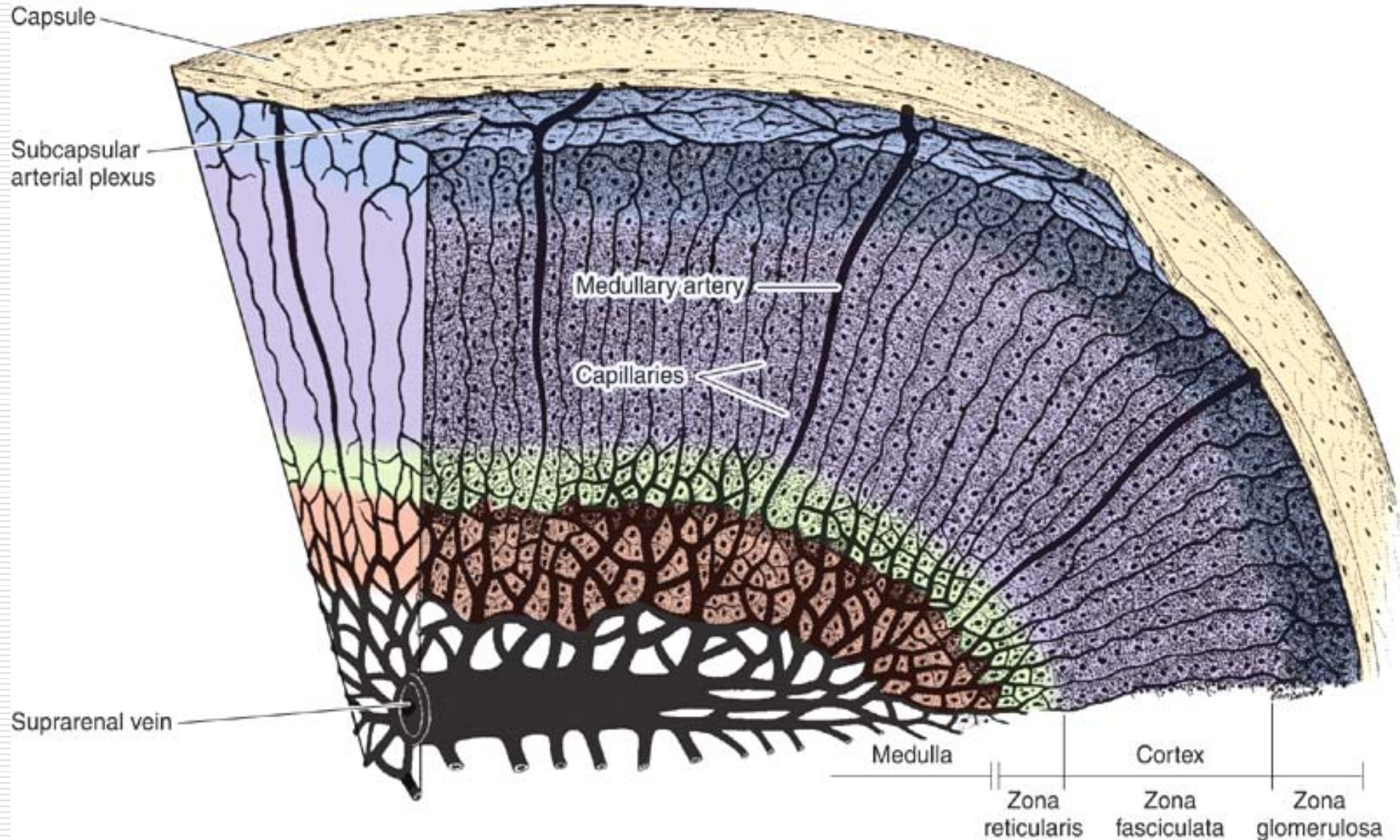


Adrenal medulla



↑ Centre vein

Blood supply of the adrenal gland



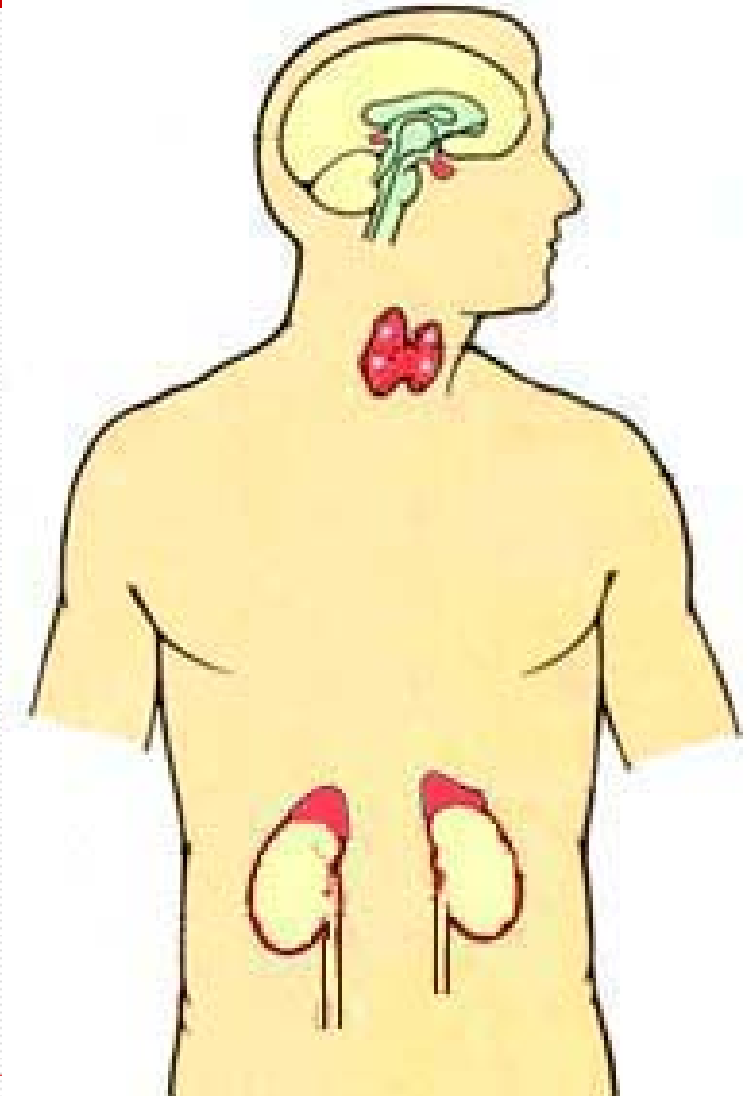
Structural components of the endocrine system

□ Endocrine glands

- **Thyroid gland**
- **Parathyroid gland**
- **Adrenal gland**
- Hypophysis
- **Pineal body**

□ **Endocrine cells**

- Protein-secreting cells
- Steroid-secreting cells



Hypophysis

Capsule

□ Adenohypophysis

■ Pars distalis ————— Anterior lobe

■ Pars intermedia

■ Pars tuberalis

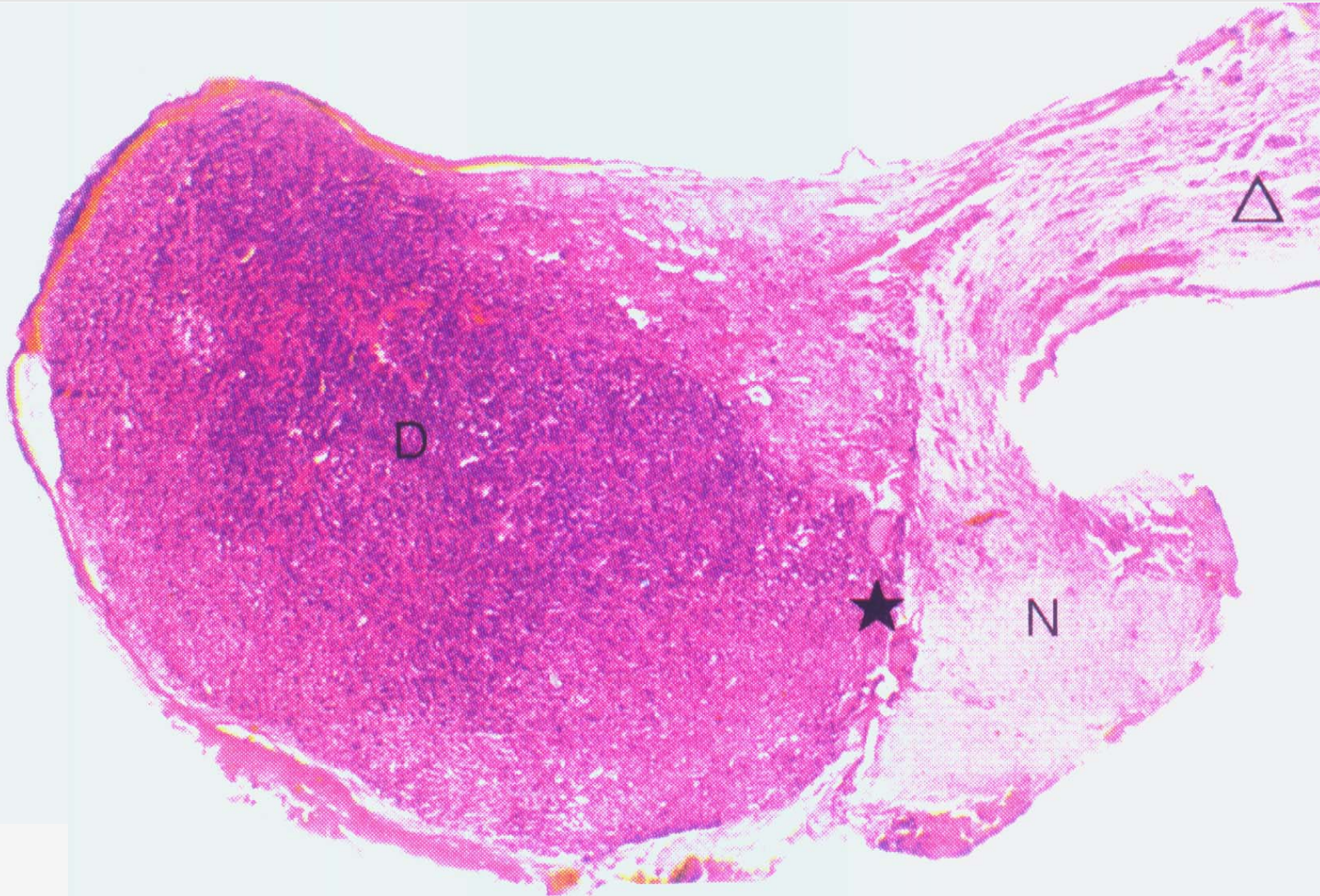
□ Neurohypophysis

■ Pars nervosa

■ Infundibulum

Posterior lobe

Hypophysis



D:Pars distalis ★ Pars intermedia N:Pars nervosa △ Infundibulum

Pars distalis of adenohypophysis

□ Acidophilic cell

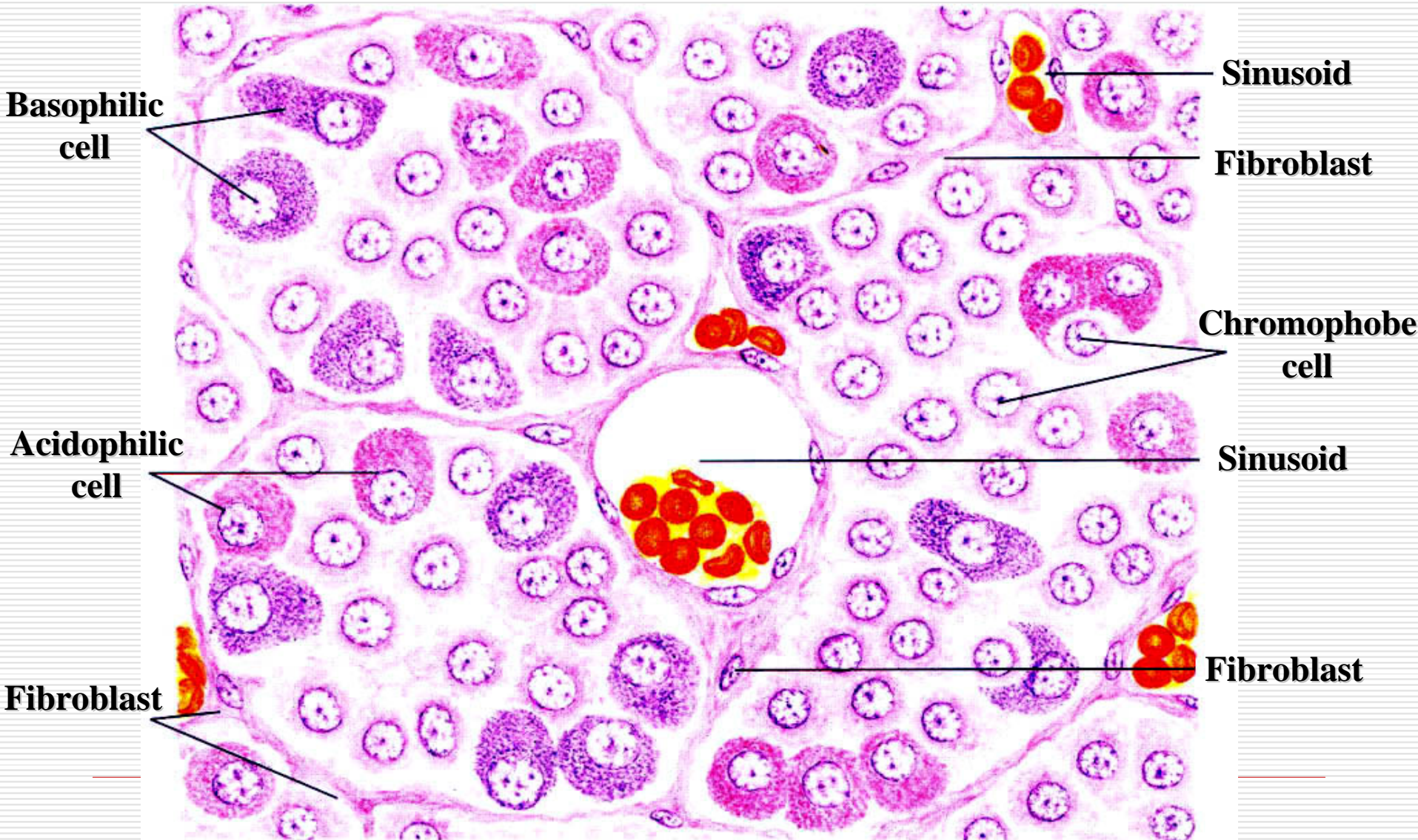
- Somatotroph (STH cell) : growth hormone , GH
- Mammotroph : mammotropin

□ Basophilic cell

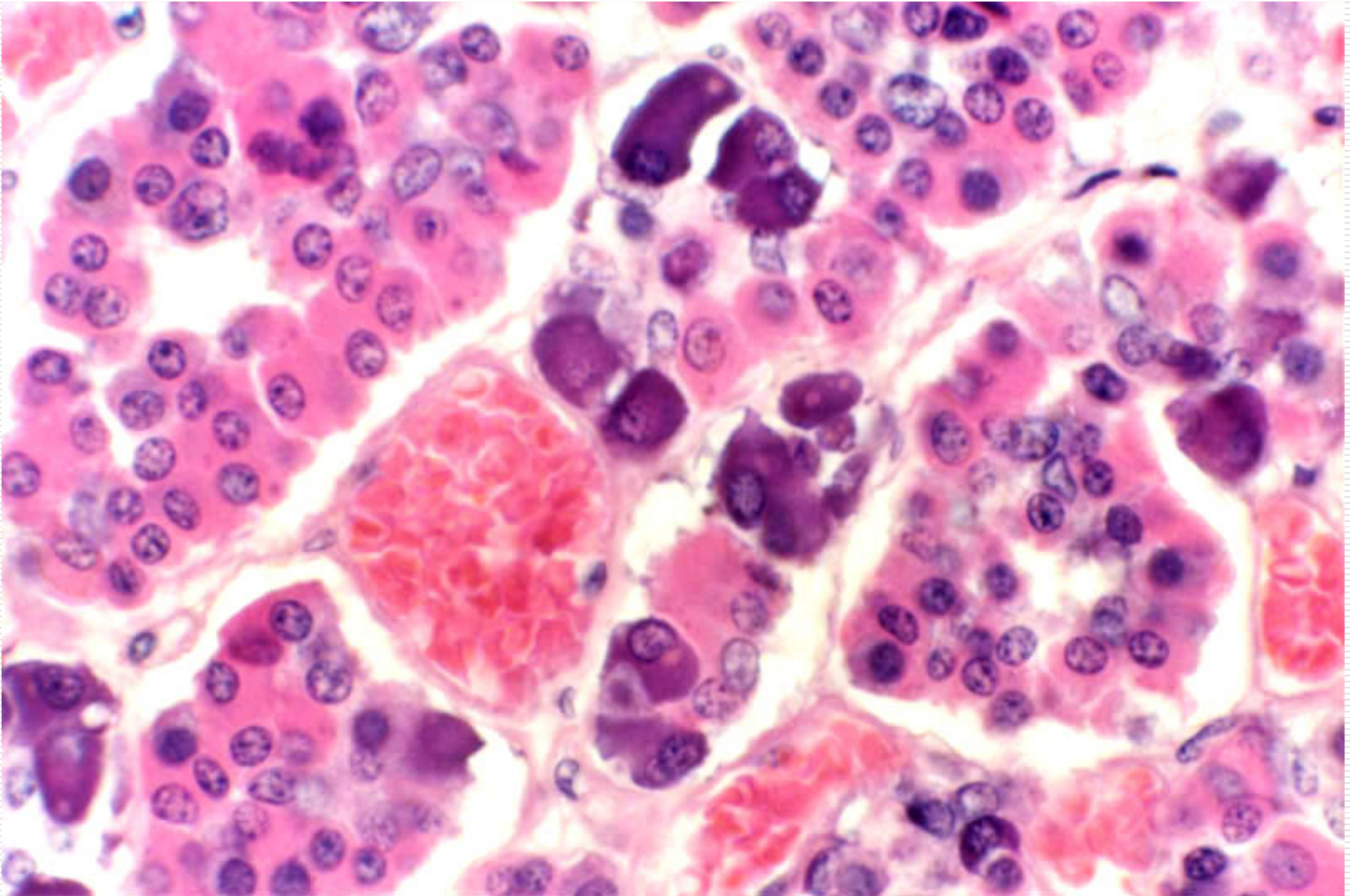
- Thyrotroph : thyroid stimulating hormone, TSH
- Gonadotroph : follicle stimulating hormone , FSH
luteinizing hormone, LH
(interstitial cell stimulating hormone , ICSH)
- Corticotroph : adenocorticotrophic , ACTH
lipotropic hormone , LPH

□ Chromophobe cell

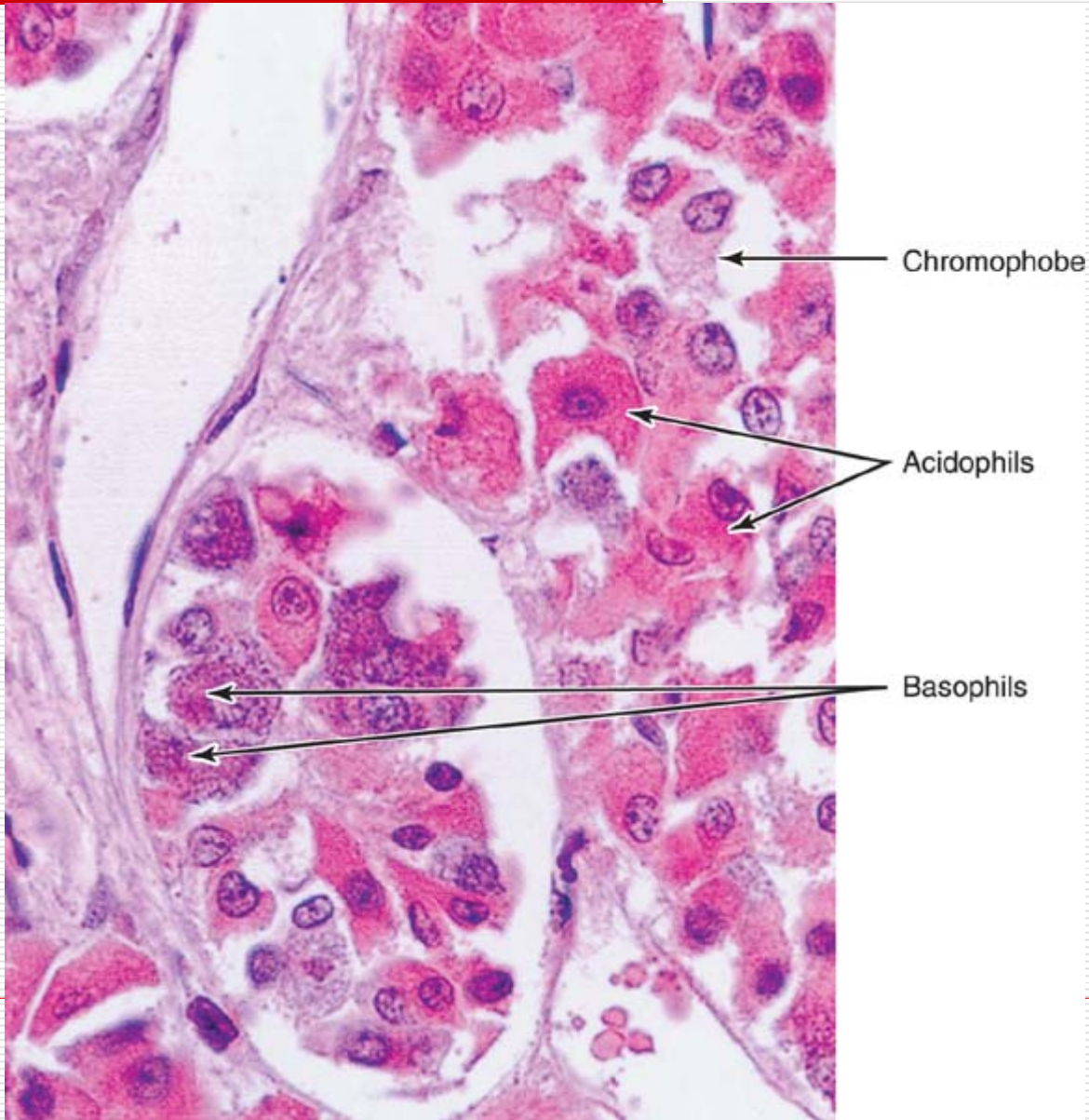
Pars distalis of adenohypophysis



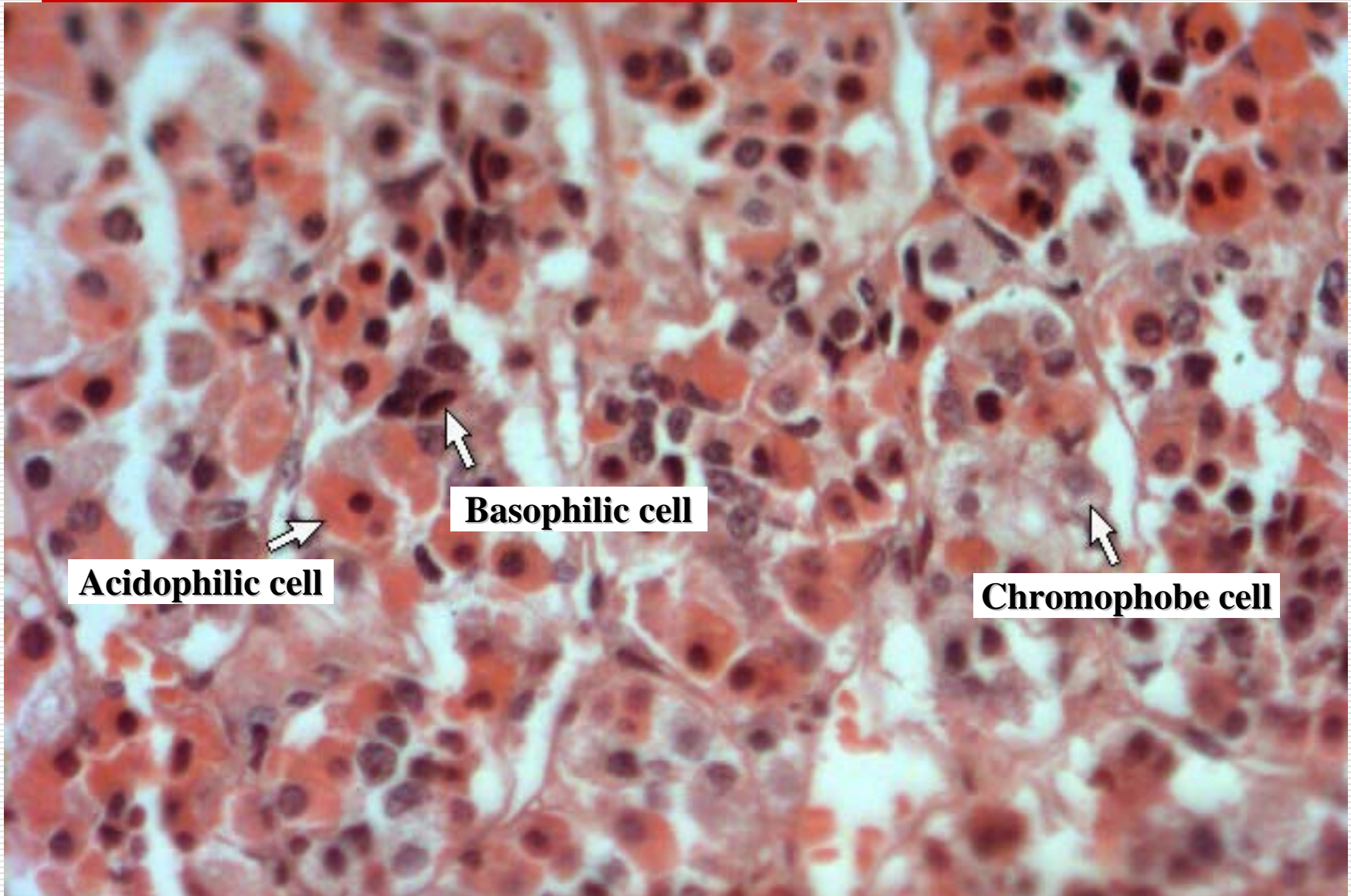
Pars distalis of adenohypophysis



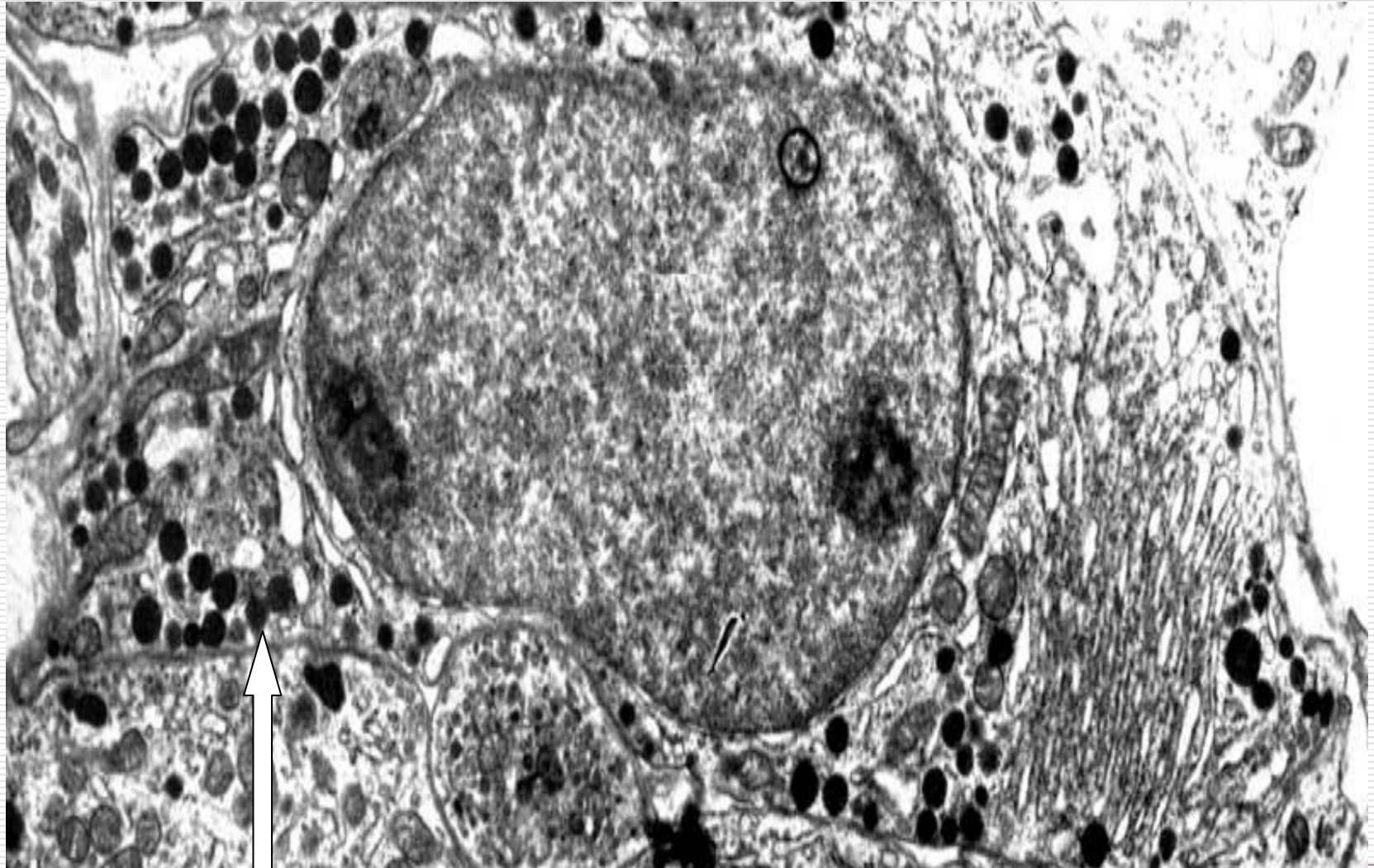
Pars distalis of adenohypophysis



Pars distalis of adenohypophysis

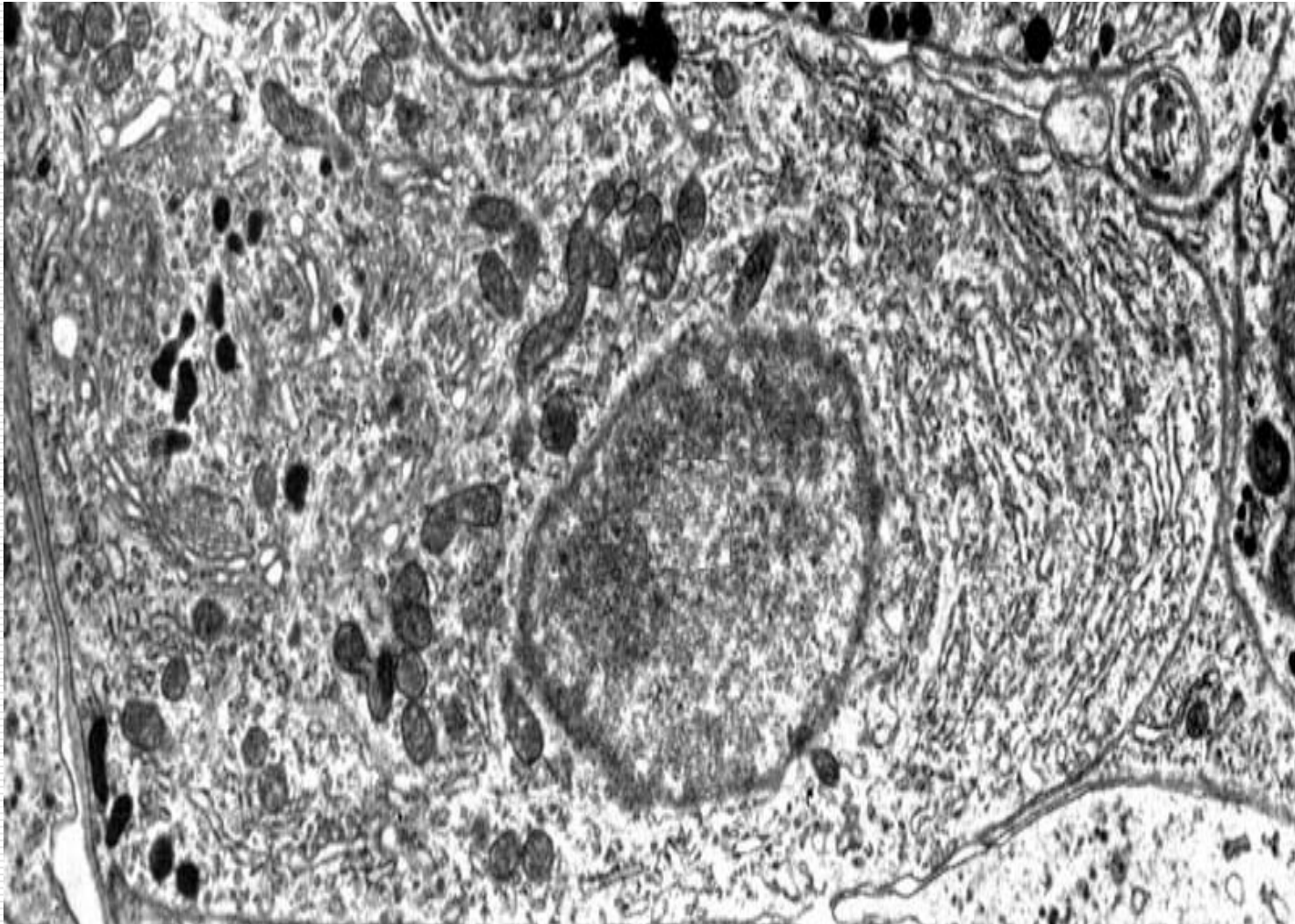


Somatotroph (STH cell)

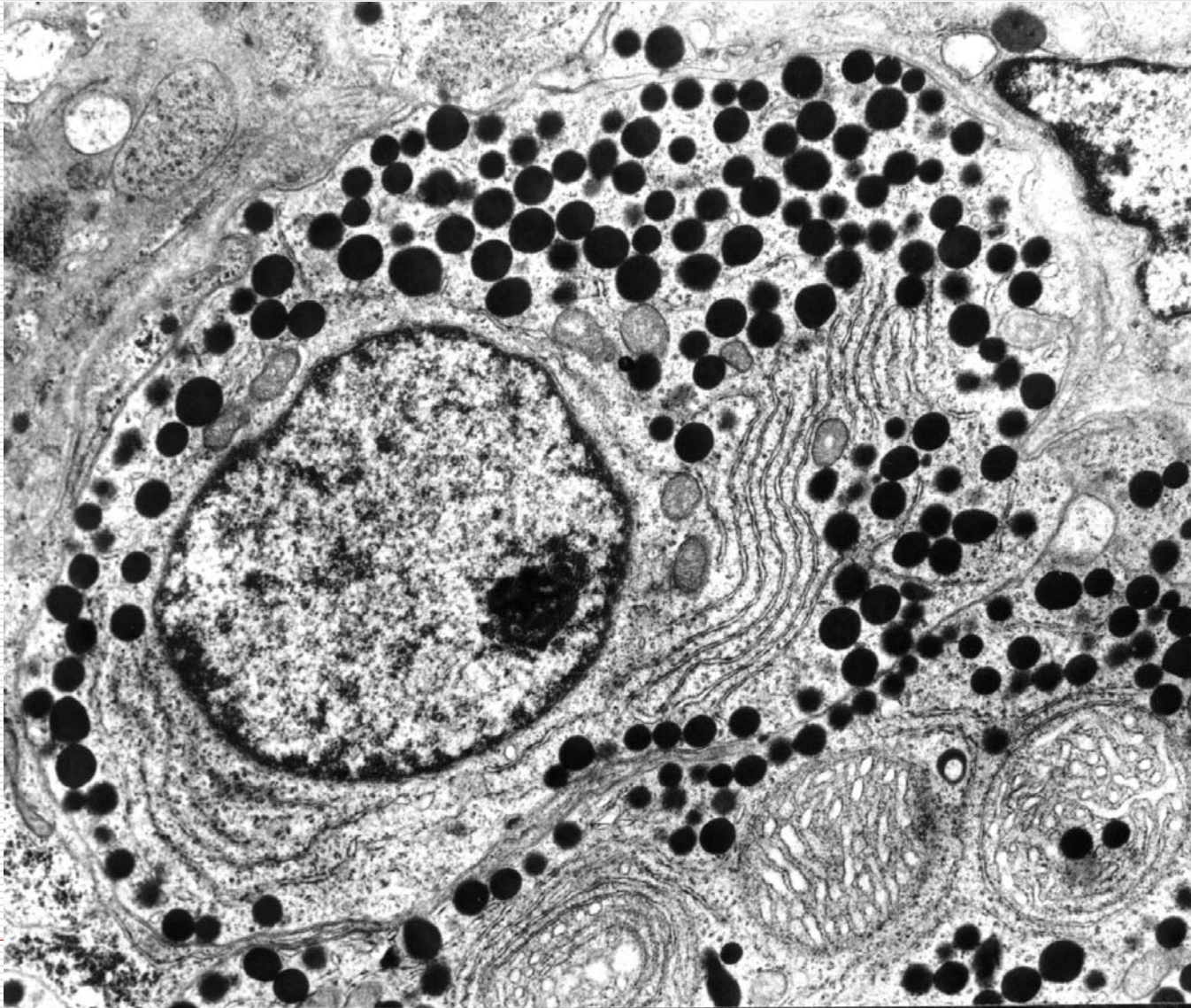


↑
Secretory granule

Mammotroph



Corticotroph (ACTH cell)



Hypophysis

Capsule

□ Adenohypophysis

■ Pars distalis ————— Anterior lobe

■ Pars intermedia

■ Pars tuberalis

□ Neurohypophysis

■ Pars nervosa

■ Infundibulum

Posterior lobe

Pars intermedia of adenohypophysis

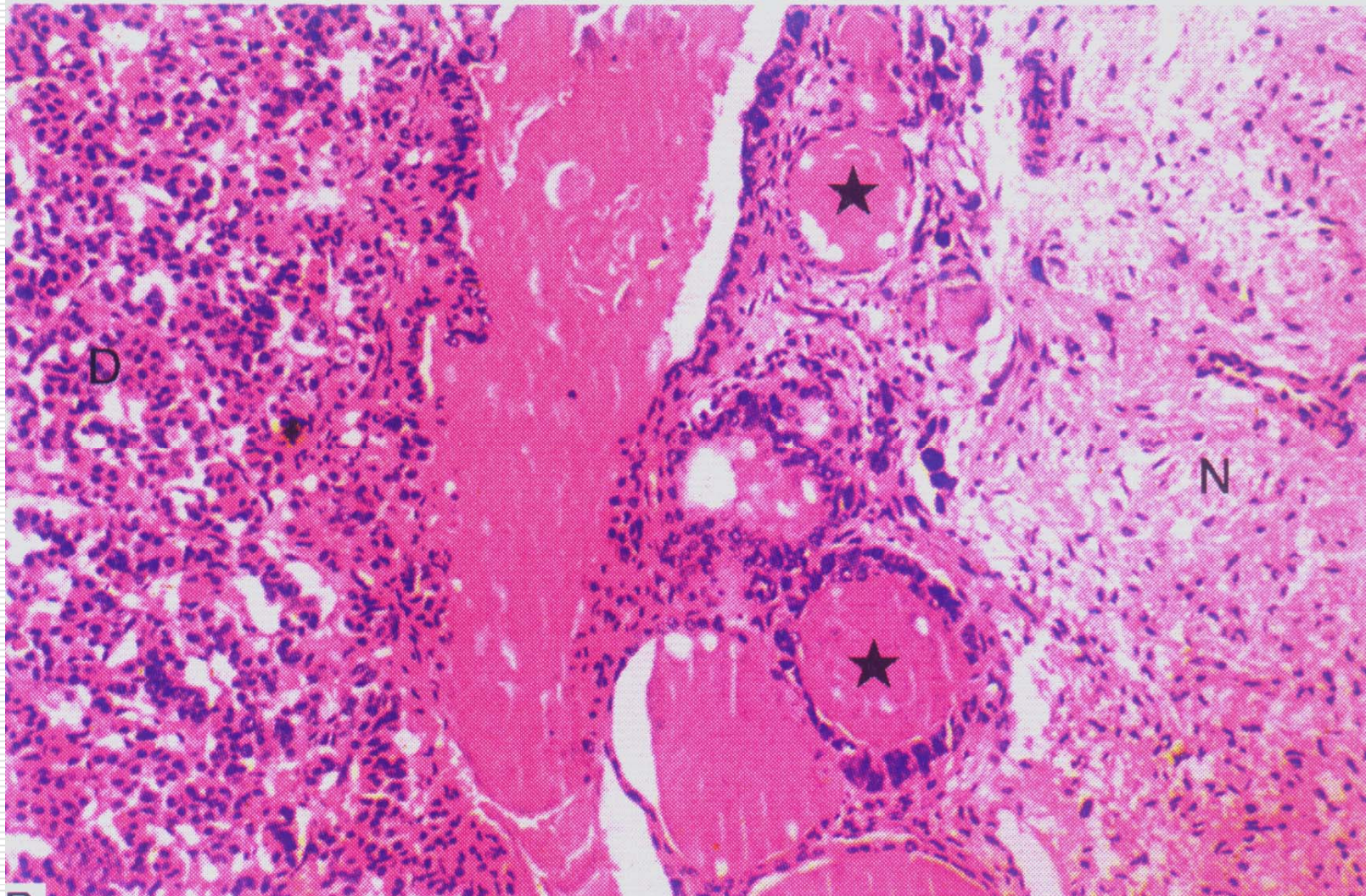
□ Structure

- Chromophobe cells
- Basophilic cells
- Follicles

□ Function

- Produce melanocyte stimulating hormone, MSH
-

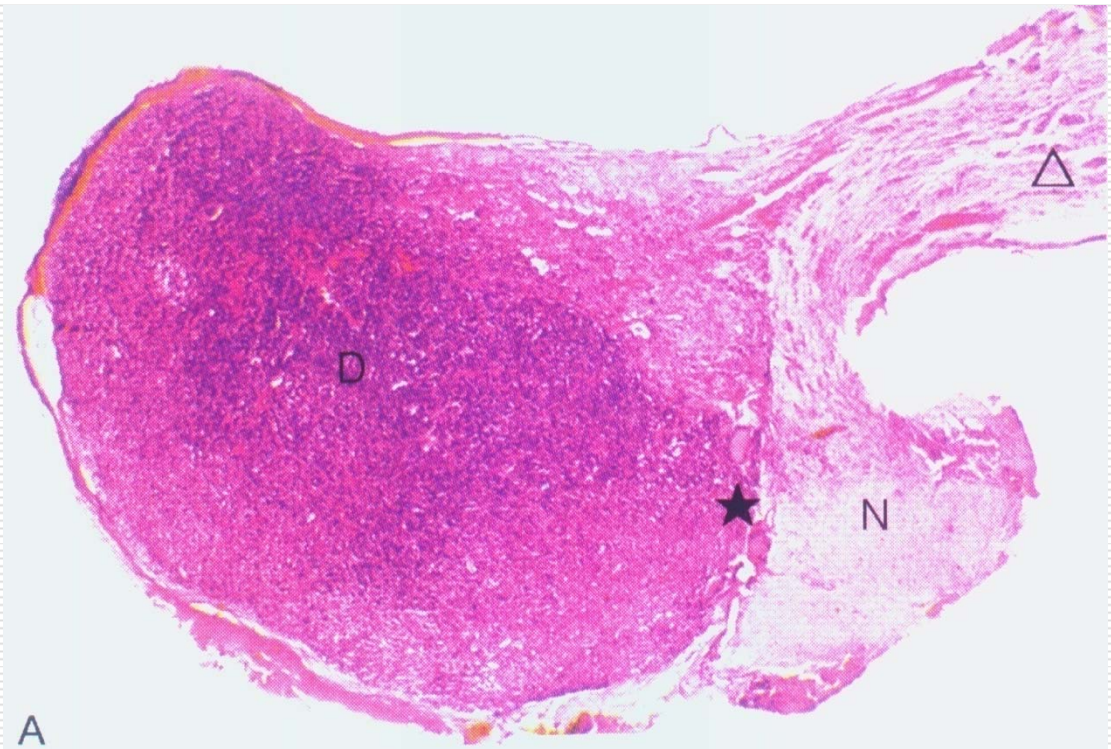
Pars intermedia of adenohypophysis



D:Pars distalis ★ Pars intermedia N:Pars nervosa

Pars tuberalis of adenohypophysis

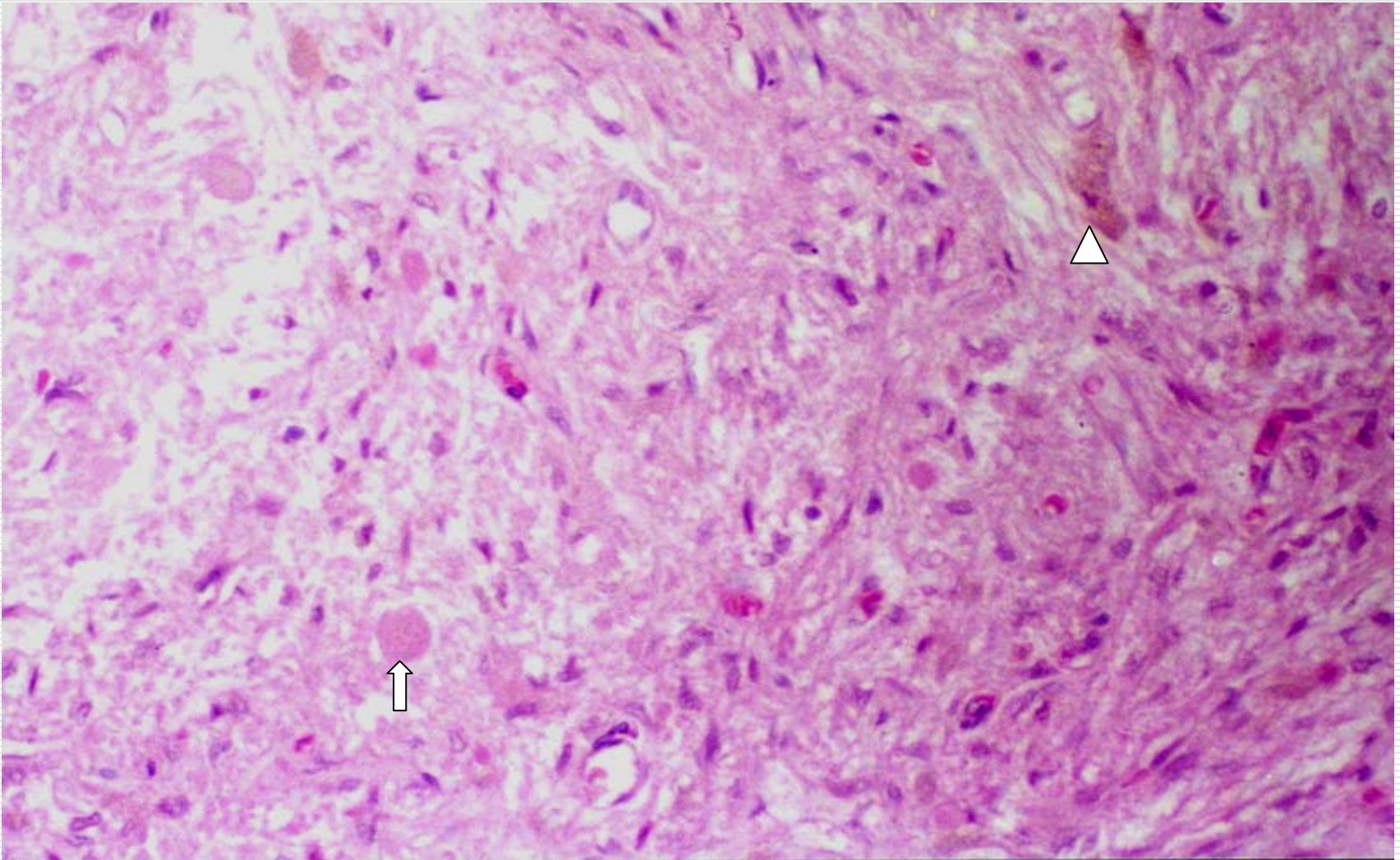
- ❑ Chromophobe cells
- ❑ Acidophilic cells
- ❑ Basophilic cells



Neurohypophysis

- Unmyelinated nerve fibers
 - Herring body
 - The hypothalamo - neurohypophyseal system
 - **Supraoptic nucleus**
 - **Antidiuretic hormone (ADH)**
 - **Vasopressin (VP)**
 - **Paraventricular nucleus**
 - **Oxytocin (OT)**
 - Glial cell (pituicyte)
-

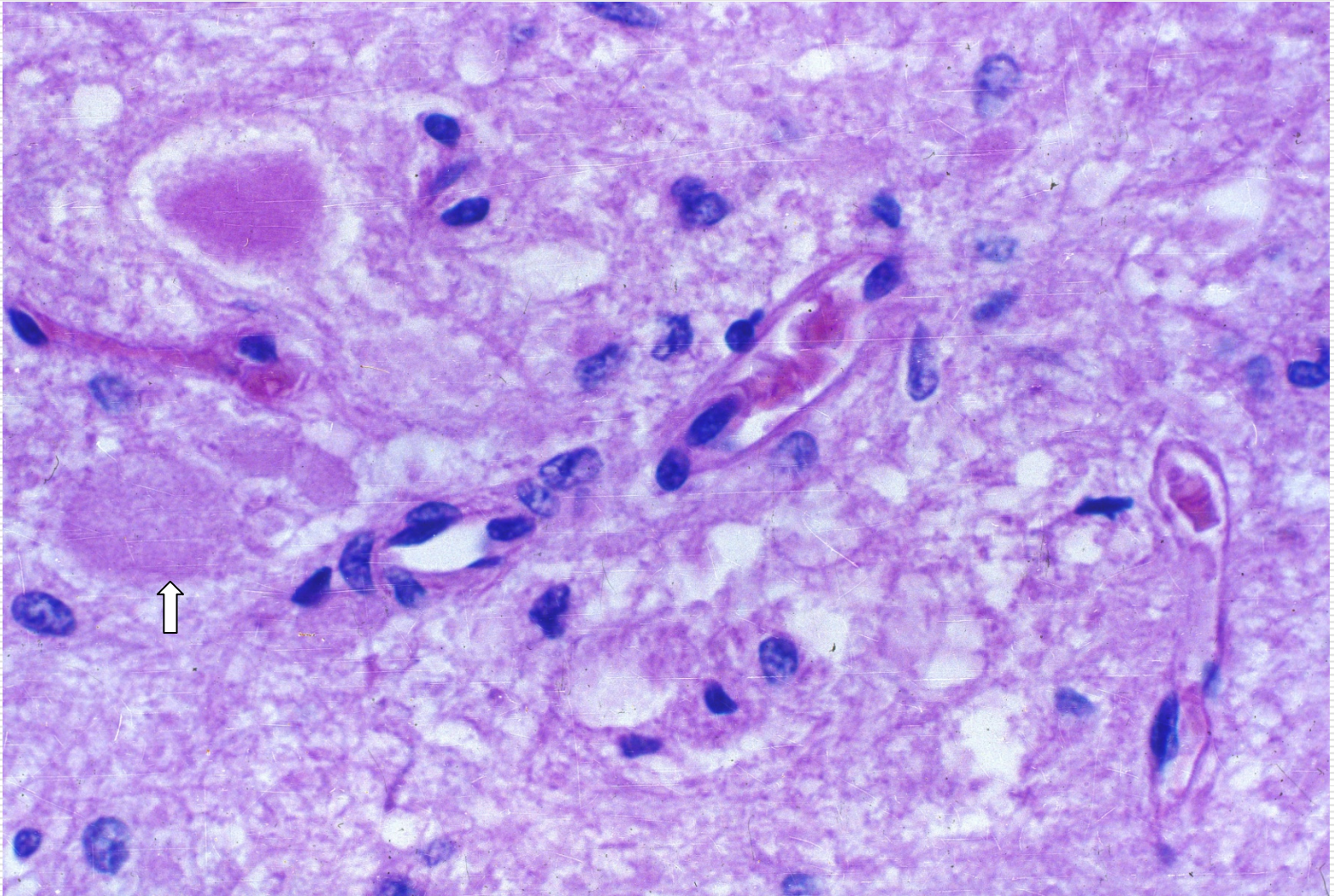
Neurohypophysis



↑ Herring body

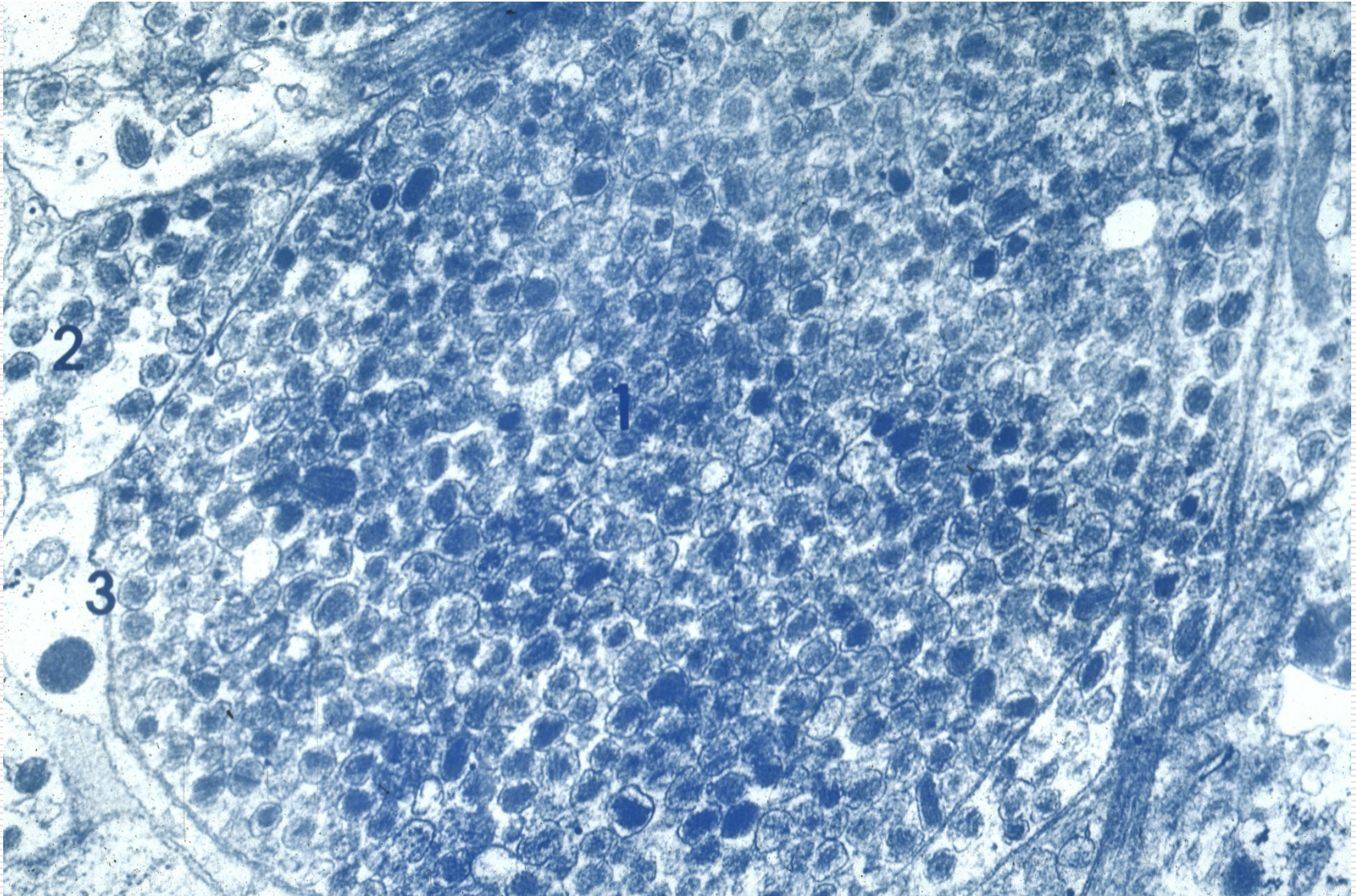
△ Pituicyte

Neurohypophysis

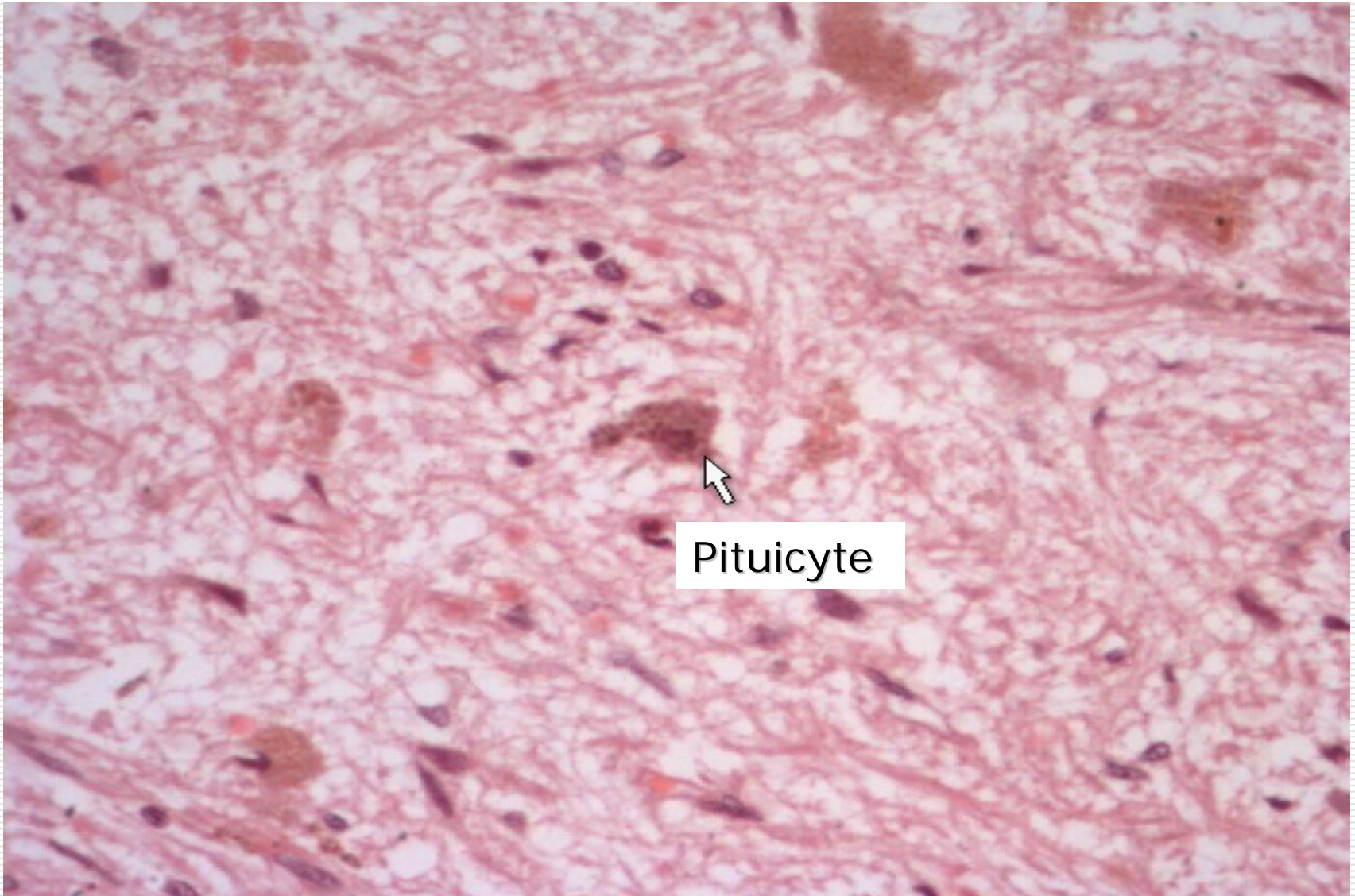


↑ Herring body

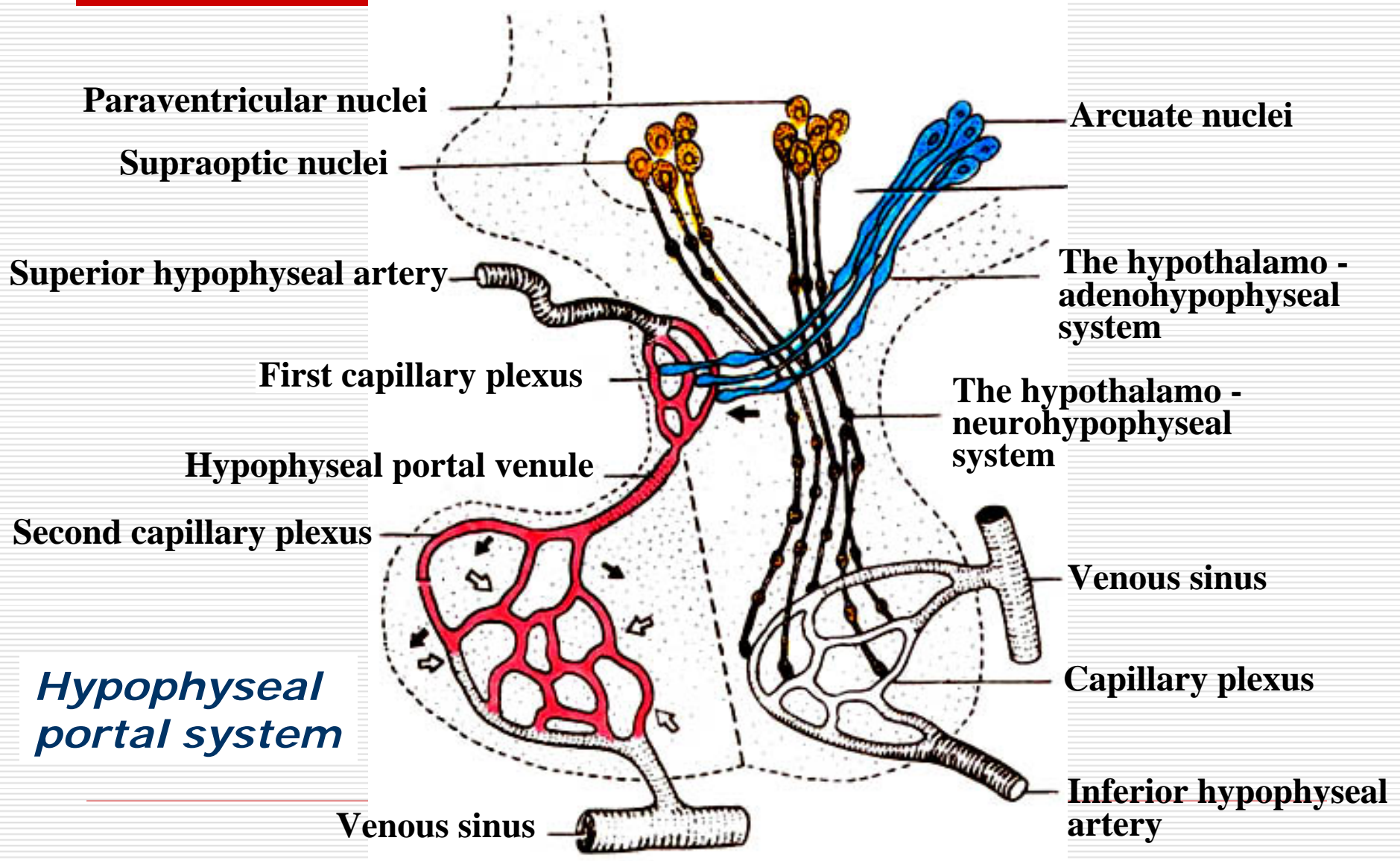
Herring body of neurohypophysis

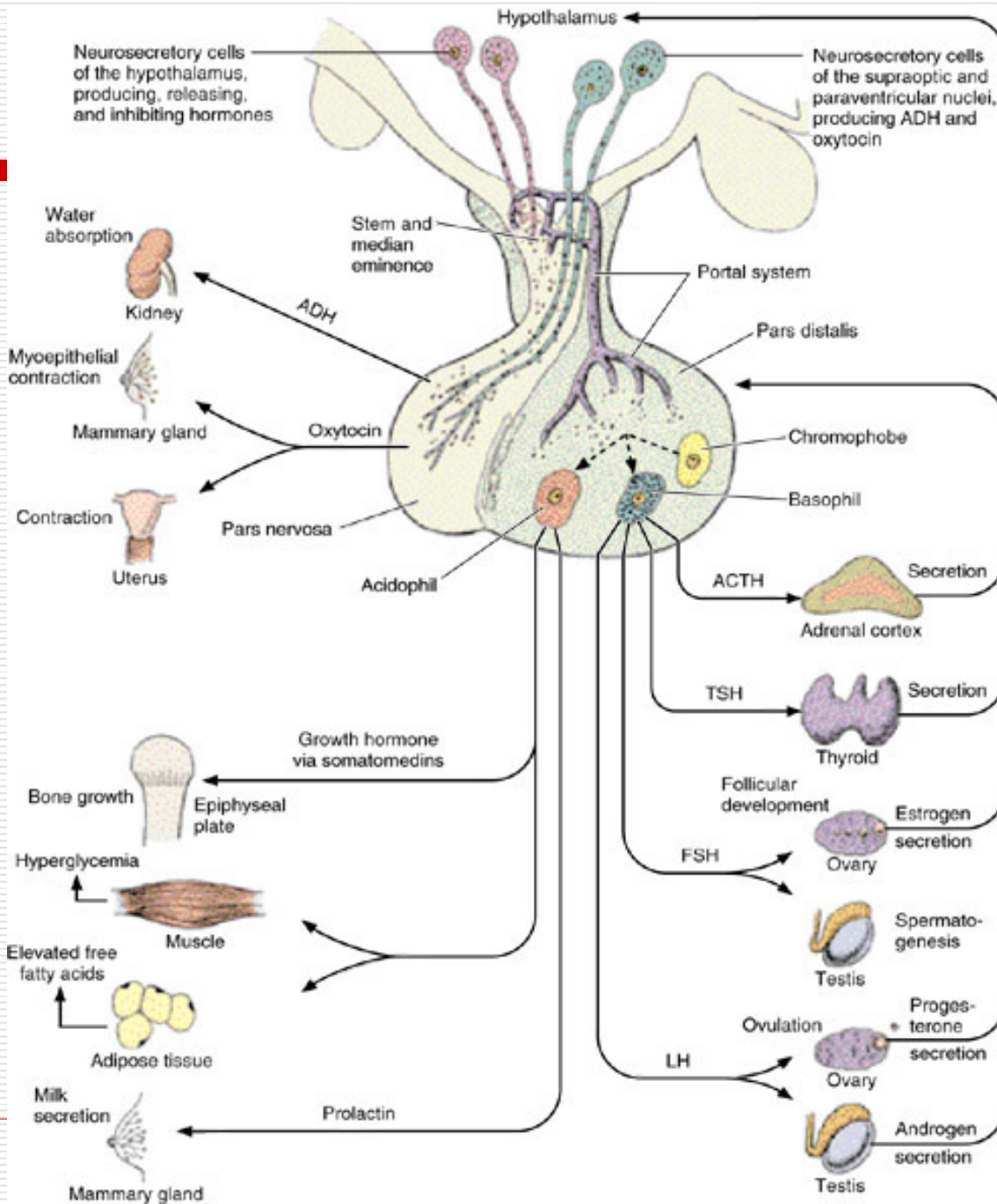


Neurohypophysis



Blood supply of hypophysis





The effects of various hypophyseal hormones on target organs and the feedback mechanisms that control their secretion.

The relationship between hypothalamus and adenohypophysis

□ The hypothalamo - adenohypophyseal system

- Neurosecretory cells**
 - Releasing hormone (RH)**
 - Release inhibiting hormone (RIH)**
-

Summary

- ❑ **Master the structure and functions of thyroid gland, parathyroid gland and adrenal gland.**
 - ❑ **Master the microstructure and secreting hormones of hypophysis, the relation of hypophysis and hypothalamus.**
 - ❑ **Understand the composition of endocrine system, conceptions of endocrine and paracrine. Know the ultrastructure of endocrine cells of excreting nitrogenous hormone and steroid hormone.**
 - ❑ **Understand the structure and functions of pineal body.**
 - ❑ **Know neuroendocrine-immunoregulatory network generally.**
-